

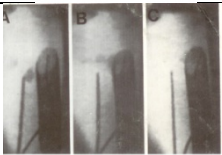
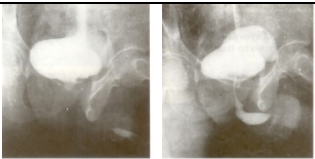


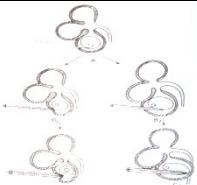
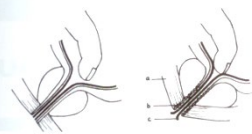
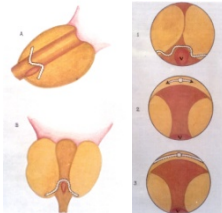
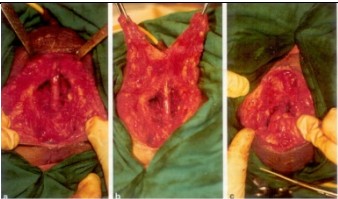
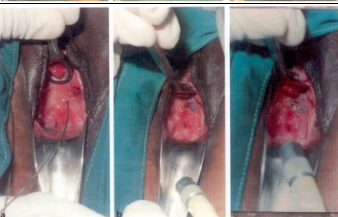
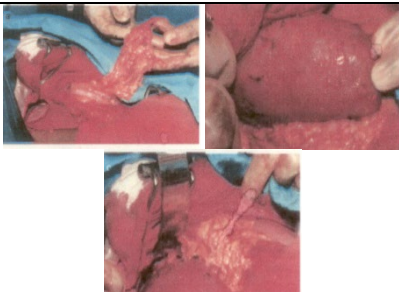
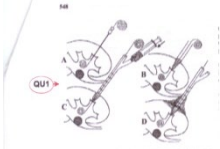
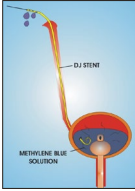
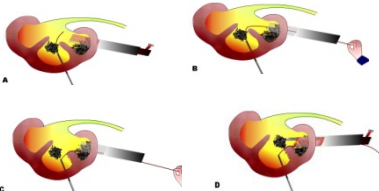
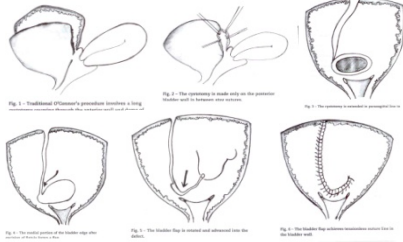
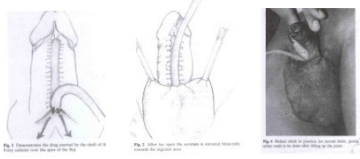
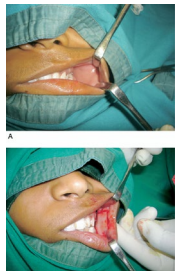
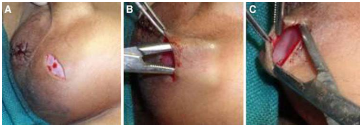
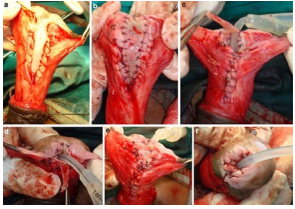
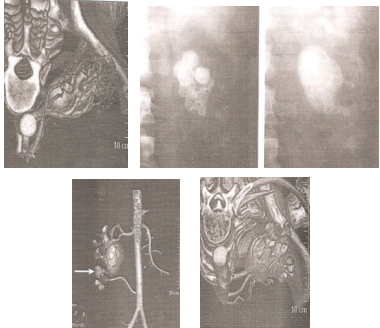
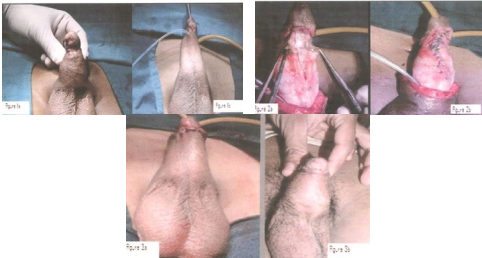
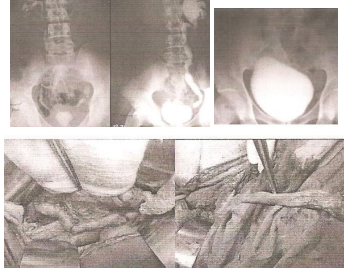
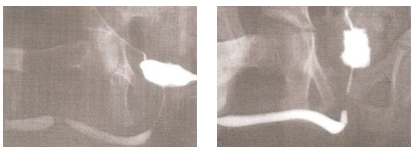

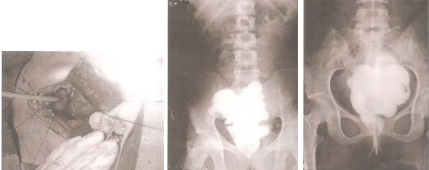

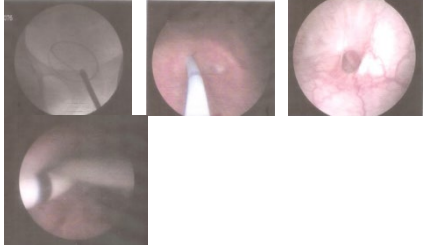
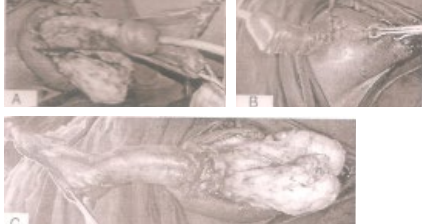
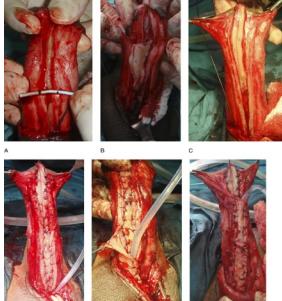
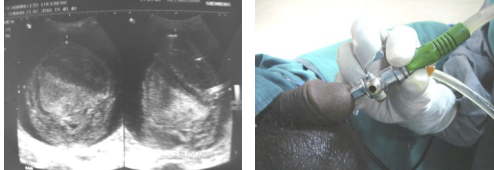


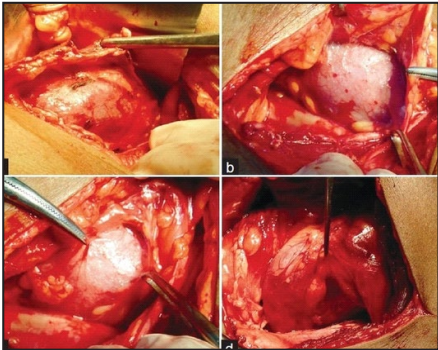
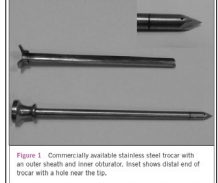

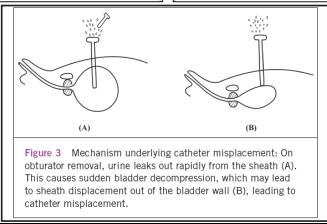
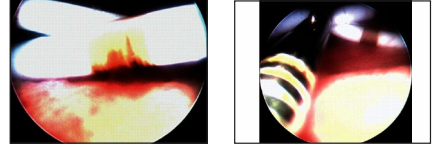

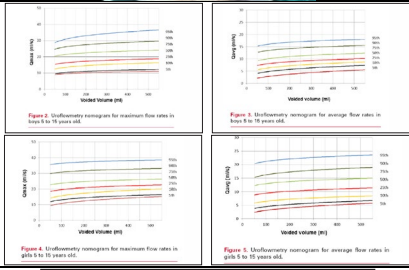
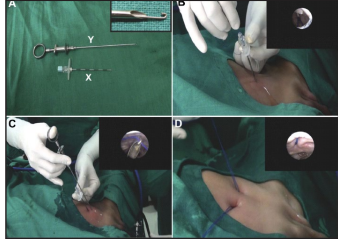
Techniques Contributed to the Science of Urology




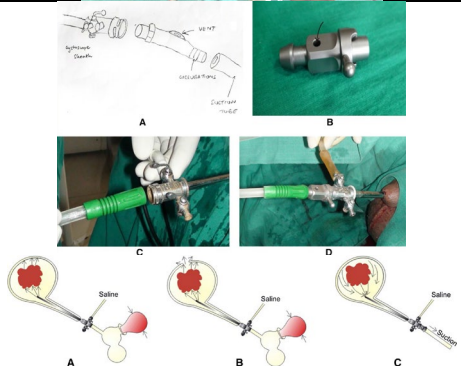
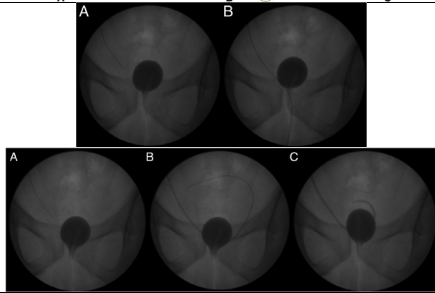
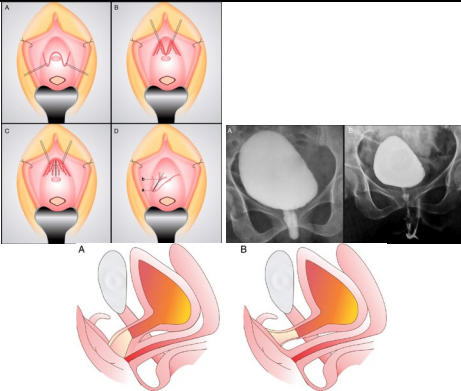
| Year | Title | |
|------|---|---|
| 1992 | Dalela D., Ahlawat R., Mishra V.K. Prevesical ureteric calculi: A modified prone position for treatment with extracorporeal shock wave lithotripsy using lithostar. Brit J Urol 1992; 70: 456-457. |  |
| 1992 | Goel T.C., Dalela D. The "Nipple" urethral office following total penectomy. Brit J Urol 1992; 70:576-577. |  |
| 1993 | Ahlawat R., Dalela D. "Intraoperative percutaneous caliceal irrigation"-A technique for clearing caliceal residue during percutaneous surgery. Brit J Urol 1993; 72:990. |  |
| 1994 | Dalela D., Masood S., Singh K.M. Percutaneous cystoscopy assisted urethral synechiotomy- a method to obtain an antegrade urethrogram in traumatic urethral stricture. Brit J Urol 1994; 74:795-796. |  |
| 1995 | Harish A., Chandra H, Dalela D. Induction of regeneration by bladder mucosal graft: a new approach in the management of "Difficult" vesico-urethro-vaginal fistula. Indian J Urol 1995; 12: 4. |  |
| 1997 | Dalela D., Kushwaha R., Singh K.M., Chandra H. Pneumo-urethrography: a cost effective method for follow up of anterior urethral strictures. Indian J Urol 1995; 12:70. |  |
| 1997 | Dalela D, Agarwal R, Singh KM. "The wire coil sign"- a fluoroscopic guide to enhance the accuracy of tract dilation for PCN in giant hydronephrotic kidneys. Indian J Urol 1997; 14: No 1 |  |
| 1999 | Chandra H., Dalela D., Pahwa H.S. Digital pushdown of prostate - a technique to improvise the access of proximal urethral end during bulbo prostatic anastomosis. Indian J Urol 1999; 15: 172-173. |  |
| 2000 | Dalela D., Singh K. M., Agarwal R. Chandra H. Transurethral circum-apical incision of prostate (TUCIP) - minimizing sphincteric injury during transvesical prostatectomy for large prostates. Brit J Urol 2000; 996-997. |  |

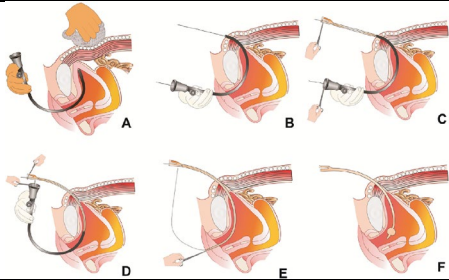
| | | |
|-------------|---|---|
| <p>2002</p> | <p>Dalela D., Pawha H.S., Chandra H. & Singh K.M. Paratesticular fibro-adipose tissue flap: an alternate for post pubectomy dead space obliteration. Brit J Urol 2002; 89:1-2.</p> |  |
| <p>2002</p> | <p>Dalela D., Singh K.M., Arora Rajesh, Tandon Vipul. Transvaginal electrocauterization along with submucosal injection of autologous blood- A simple technique to manage a miniature VVF. Brit J Urol 2002; 89:1-3.</p> |  |
| <p>2004</p> | <p>Dalela D., Gupta V. P., Goel Apul, Singh K.M. "Omental wrap" of renal pedicle- A new step to minimize the recurrence of chyluria following pyelolymphatic disconnection. BJU International 2004; 94 (4): 673-4.</p> |  |
| <p>2004</p> | <p>Dalela D., Goel Apul, Singh Pratipal, Shankwar S. N. Renal capsular block: a novel method for performing percutaneous nephrolithotomy under local anesthesia J Endourol 2004; 18 (6): 544-6</p> |  |
| <p>2004</p> | <p>Singh K.M., Goel A., Sankhwar S. N., Dalela D. Confirmation of the correct placement of lower end of DJ Stent during Open surgery: Point of Technique. International Urol Nephrol, 2004; 36:335-6.</p> |  |
| <p>2006</p> | <p>D. Dalela, Goel A, Sankhwar S.N. , Ahuja M, Singh V., Bhandari M. Guide wire assisted infundibular tilt-GAIT- solving problems of accessibility during PCNL in hydronephrotic kidneys. J Endourol 2006 20: 620-1, 2006.</p> |  |
| <p>2006</p> | <p>Dalela D., Ranjan P., Sankhwar P.L., Shankwar S.N., Naja V., Goel A. Supratrigonal VVF repair by modified O'connor's technique: an experience of 26 cases Eur Urol, 2006; 49(3):551-6.</p> |  |

| | | |
|------|---|---|
| 2007 | Ranjan P, Dalela D, Goel A, Sankhwar SN, Singh V. Scrotal hitch procedure to prevent necrosis of scroto-perineal flap apex during lay urethroplasty. Int Urol Nephrol 2007; 39:119-121. |  |
| 2008 | Goel Apul, Dalela D., R. J. Sinha & S. N. Sankhwar, Harvesting buccal mucosa graft under local infiltration analgesia - mitigating need for general anesthesia. Urology 2008; 72: 675-676. |  |
| 2008 | Dalela D., Sinha R. J., Goal A & Sankhwar S.N., Balloon distension of scrotum: a step to facilitate creation of dartos pouch during orchiopexy Pediatr Surg Int 2008; 24:437-438. |  |
| 2009 | Goel A, Goel A, Dalela D, Sankhwar SN. Meatoplasty using double buccal mucosal graft technique. International Urol Nephrol 2009;41(4):885-7. |  |
| 2009 | Dalela D, Gupta A, Ahmed S, Goel A. Three-Dimensional Synchronized Multidirectional Renal Pyelo-Angiography: A New Imaging Concept to Facilitate Percutaneous Nephrolithotomy in Technically Challenging Cases. Journal of Endourology . December 2009; 23:(12) 1937-1939. |  |
| 2009 | Sinha RJ, Dalela D, Sankhwar SN, Singh V. Urethral fistula following circumcision: salvaged by buccal mucosa graft urethroplasty. Indian J Urol 2009; 71:89-91. |  |
| 2009 | Vengatesh K. Sengottayan, Pawan Vasudeva, Dalela D. Ureterocystoplasty: a novel approach to augment small capacity urinary bladder in adults. Indian J Urol 2009; 71:151-153. |  |

| | | |
|------|---|--|
| 2009 | Goel A, Gupta A, Dalela D. Antegrade urethrogram: A technique to visualize the proximal bulbous urethral segment in anterior urethral stricture. Indian J Urol. 25: 415-6, 2009. |  |
| 2010 | Dalela D, Sinha RJ, Sankhwar SN, Singh V. Ventral Bulbar Augmentation – A new technical modification of oral mucosa graft urethroplasty for stricture of the Proximal Bulbar Urethra. Urology Journal 2010;7:2 |  |
| 2010 | Singh Vishwajeet, Sinha R.J., Sankhwar S.N.. Reconstructive surgery for tuberculous contracted bladder: experience of a center in northern India. Int. Urol. Nephrol. 2011 43(2):423 |  |
| 2010 | Goel A*, Singh D, Sengottayan VK, Sankhwar SN. Non-dismembered ureteroplasty for congenital midureteral stenosis: A new application of an old technique. Urology, 76:1004-6, 2010. |  |
| 2011 | Singh Vishwajeet, Mandhani Pallavi, Mehrotra Seema, Sinha R.J. Cystohysteroscopy: Novel use of Semi-rigid ureteroscope to Establish an access via fistulous tract between urinary bladder and vagina for confirming the diagnosis and facilitating laparoscopic repair of vesicouterine fistula. Journal of Endourology 2011;25(6);913 |  |
| 2011 | Vishwajeet Singh, Rahul Janak Sinha, S.N.Sankhwar, Vijay Kumar. Reconstructive Surgery for Penoscrotal Filarial Lymphedema: A decade of experience and follow-up Urology 2011 77(5):1228 |  |
| 2011 | Goel A*, Goel A, Jain A. Buccal mucosal graft urethroplasty for penile stricture: only dorsal or combined dorsal and ventral graft placement? Urology, 77(6):1482-6, 2011. Doi: 10.1016/j.urology.2010.12.058. PMID: 21354596 |  |
| 2011 | Goel A*. Reply by author. Goel A, et al. Mechanical suction: an effective and safe method to remove large and tenacious clots from the urinary bladder. Urology, 77: 494-6, 2011. |  |

| | | |
|-------------|---|---|
| <p>2012</p> | <p>Goel A. Gerota's fascia over a pelvic ectopic kidney: Myth or reality? Indian J Urol 28: 70-73, 2012. Doi: 10.4103/0970-1591.102712. PMID: 23204662</p> |  |
| <p>2012</p> | <p>Goyal NK, Goel A*, Sankhwar SN. Safe percutaneous suprapubic catheterization. Ann R Coll Surg Engl 94: 597-600, 2012. PMID: 23131233</p> |    |
| <p>2012</p> | <p>Yadav R, Dalela D, Goyal NK, Nagathan D, Sankhwar SN. "Bilateral Double J Stent Removal: The way to do it!" Doi: 10.4103/2006-8808.110273 Journal of Surgical Technique and Case Report 2012;Vol-4(2):138-139.</p> |  |
| <p>2012</p> | <p>Dwivedi A, Kathpalia R, Yadav R, Kumar M, Dalela D, Goel A, Sankhwar SN. Catheter-controlled dilatation of suprapubic tract: a novel technique for antegrade access to bladder. DOI: 10.1089/vid.2012.0045. Endourol Part B Videourology, 2012.</p> |  |
| <p>2013</p> | <p>Gupta DK, Sankhwar SN, Goel A*. Uroflowmetry nomograms for healthy children 5 to 15 years old. J Urol, 190:1008-14, 2013. Doi: 10.1016/j.juro. 2013. 03.073. PMID: 23538243</p> |  |
| <p>2013</p> | <p>Yadav R, Dalela D, Goel A, Sankhwar SN, Goyal NK, Dwivedi AK, Nagathan D. Anterior vesical hitch – A step to enhance safety of percutaneous access to bladder http://dx.doi.org/10.1016/j.jpuro.2012.10.006. Journal of Paediatric Urology, 2013; 9(3):380-383.</p> |  |

| | | |
|------|--|---|
| 2013 | <p>Rahul Yadav, Deepansh Dalela, Divakar Dalela, Rohit Kathpalia, Apul Goel, Satya N. Sankhwar Preventing Inadvertent Placement of Foley Catheter into Prostatic Urethra During Suprapubic Trocar Cystostomy: A Simple Face-saver Trick DOI: 10.4103/2006-8808.118634 J Surg Tech & Case Reports 2013;5:58-9.</p> |  |
| 2014 | <p>Goel A*, Goyal NK, Parihar A, Singh R. Magnetic resonance-retrograde pyelography: A novel technique for evaluation of chyluria. Indian J Urol 30: 115-16, 2014. Doi: 10.4103/0970-1591.124221. PMID: 24497697.</p> |  |
| 2014 | <p>Prakash Jai, Dalela Deepansh, Goel Apul, Dalela D, Kumar Manoj, Sankhwar SN, Kureel SN. Testicular rerouting orchidopexy for high inguinal undescended testes” Journal of Pediatric Surgery 2014, 49: 1311-1314.</p> |  |
| 2015 | <p>Goel A, Dalela D. Mechanical suction for clot evacuation: experience with "suction bridge" for safe and effective clot removal. Int Urol Nephrol 2015, Vol 47(5): 723-6, doi: 10.1007/s11255-015-0962-8. Epub 2015 Apr 7. PMID: 25846720.</p> |  |
| 2016 | <p>Bansal A, Gupta P, Dalela D, Dalela D. Preventing intra-urethral migration of a guidewire during antegrade placement of a JJ stent: a technical modification. BMJ Case Rep. 2016 Mar 7;2016. pii: bcr2016214921. doi: 10.1136/bcr-2016-214921. PubMed PMID: 26951444.</p> |  |
| 2016 | <p>Dalela D, Gupta P, Dalela D, Govil T, “W-V Flap: A new technique for reconstruction of Female Distal Urethral Stricture using vestibular mucosa” BMJ Case Reports 2016.doi:10.1136/bcr-2016-215309</p> |  |

| | | |
|------|---|---|
| 2016 | <p>Dalela D, Gupta P, Dalela D, Srinivas A K, Bhaskar V, Govil T, Goel A, Sankhwar SN. "Transurethral bougie guided placement of suprapubic catheter over guide wire monorail in females- A novel technique". Urology May 17, 2016; http://dx.doi.org/10.1016/j.urology.2016.05.034.</p> |  <p>The image contains six anatomical diagrams, labeled A through F, arranged in two rows of three. Each diagram shows a cross-section of the female pelvic region, focusing on the bladder and the path of a catheter. Diagram A shows the initial setup with a guide wire inserted into the bladder. Diagram B shows the guide wire being maneuvered. Diagram C shows the guide wire being pulled back. Diagram D shows the guide wire being inserted into the bladder again. Diagram E shows the guide wire being maneuvered. Diagram F shows the final placement of the suprapubic catheter over the guide wire.</p> |
|------|---|---|