

Gluteal Region-II

Dr Garima Sehgal

Associate Professor

King George's Medical University

UP, Lucknow

DISCLAIMER:

- The presentation includes images which are either hand drawn or have been taken from google images or books.
- They are being used in the presentation only for educational purpose.
- The author of the presentation claims no personal ownership over images taken from books or google images.

Structures in the Gluteal region

- Bones & joints
- Ligaments
- Muscles
- Vessels
- Nerves
- Bursae

Thickest muscle

Thickest nerve

Learning Objectives

By the end of this teaching session Gluteal region –II all the MBBS 1st year students must be able to:

- Enumerate the nerves of gluteal region
- Write a short note on nerves of gluteal region
- Describe the location & relations of sciatic nerve in gluteal region
- Enumerate the arteries of gluteal region
- Write a short note on arteries of gluteal region
- Enumerate the arteries taking part in trochanteric and cruciate anastomosis
- Write a short note on trochanteric and cruciate anastomosis
- Enumerate the structures passing through greater sciatic foramen
- Enumerate the structures passing through lesser sciatic foramen
- Enumerate the bursae in relation to gluteus maximus
- Enumerate the structures deep to gluteus maximus
- Discuss applied anatomy

Nerves of Gluteal region

(all nerves in gluteal region are branches of sacral plexus)

Superior gluteal nerve (L4,L5, S1)
Inferior gluteal nerve (L5, S1, S2)
Perforating cutaneous nerve (S2,S3)

FROM DORSAL DIVISIONS

Nerve to quadratus femoris (L4,L5, S1)
Nerve to obturator internus (L5, S1, S2)
Pudendal nerve (S2,S3,S4)

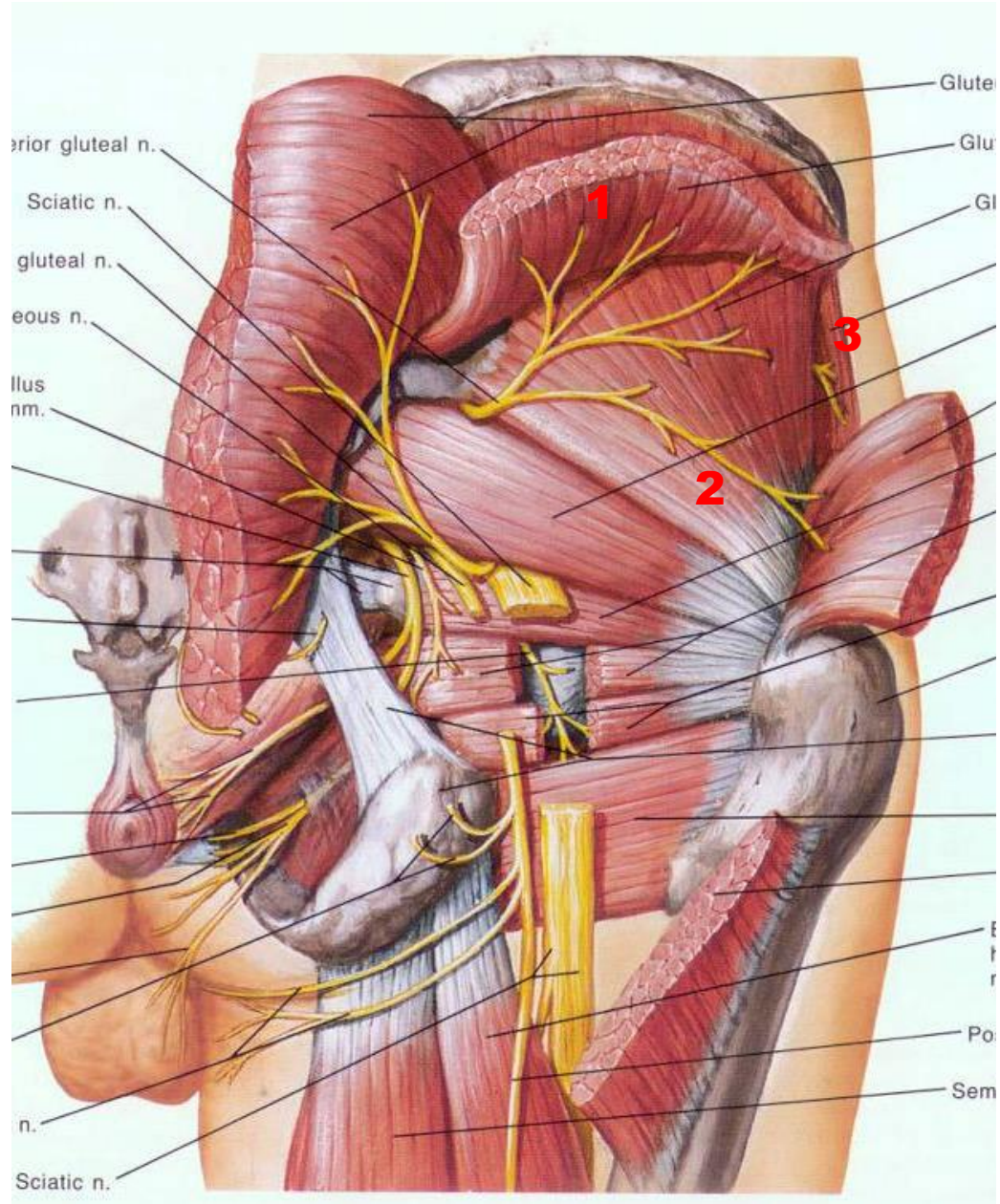
FROM VENTRAL DIVISIONS

Sciatic nerve (L4,L5,S1,S2,S3)
Posterior cutaneous nerve of thigh
(S1,S2) & (S2,S3)

**FROM BOTH DORSAL & VENTRAL
DIVISIONS**

1. Superior Gluteal nerve

(L4,L5,S1- dorsal division)



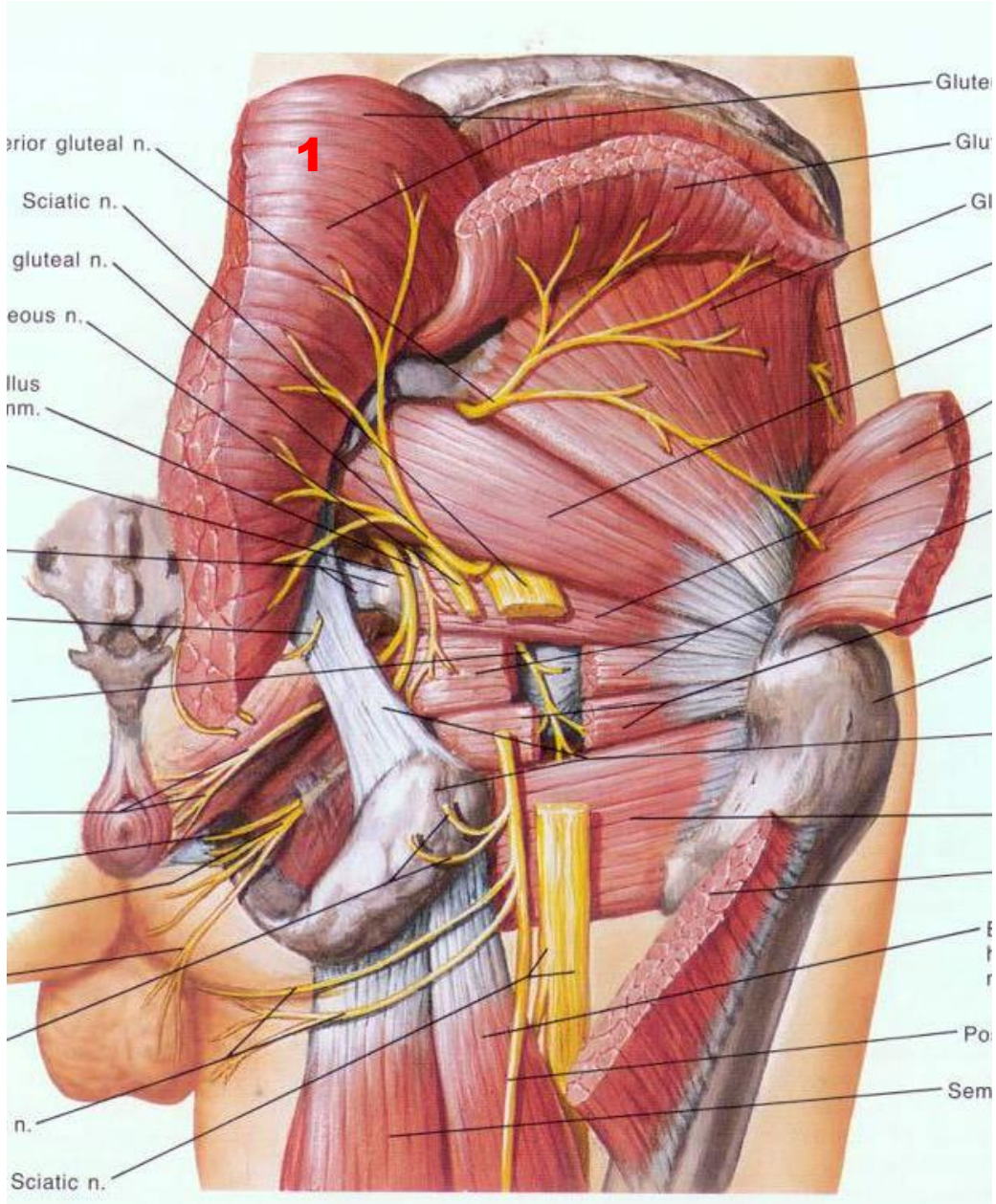
- Enters through the greater sciatic foramen
- Above piriformis
- Runs forwards between gluteus medius & gluteus minimus

• SUPPLIES:

1. Gluteus medius
2. Gluteus minimus
3. Tensor fasciae latae

2. Inferior Gluteal nerve (L5,S1,S2- dorsal division)

- Enters through the greater sciatic foramen
- Below piriformis
- **SUPPLIES:**
 1. Gluteus maximus

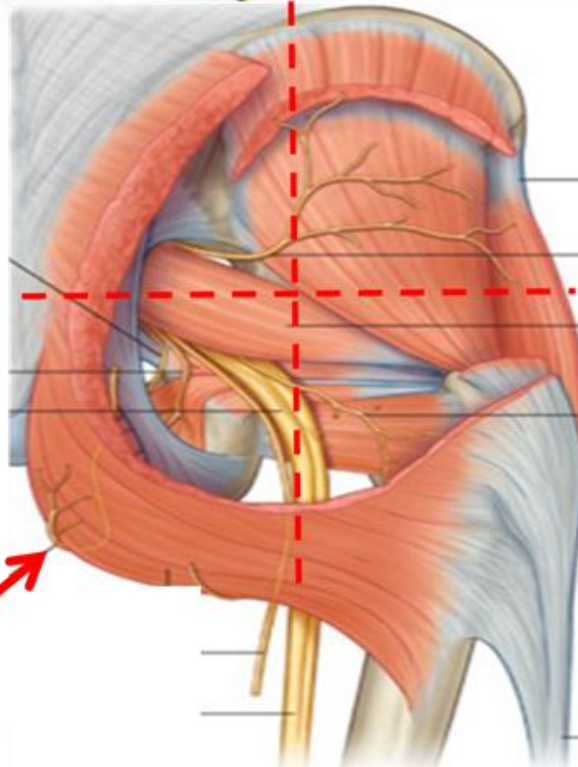
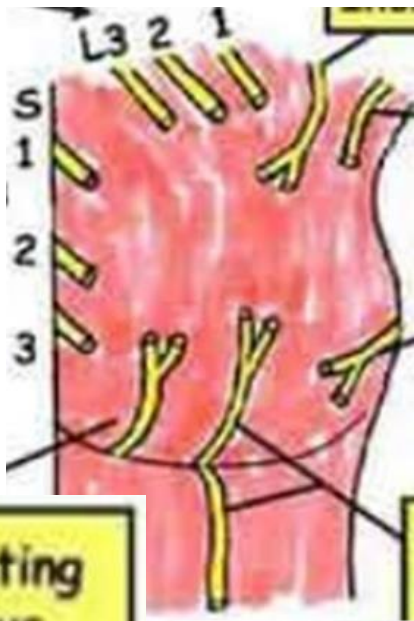


3. Perforating cutaneous nerve (S2,S3 – dorsal division)

- Pierces sacrotuberous ligament
- Winds around lower border of gluteus maximus

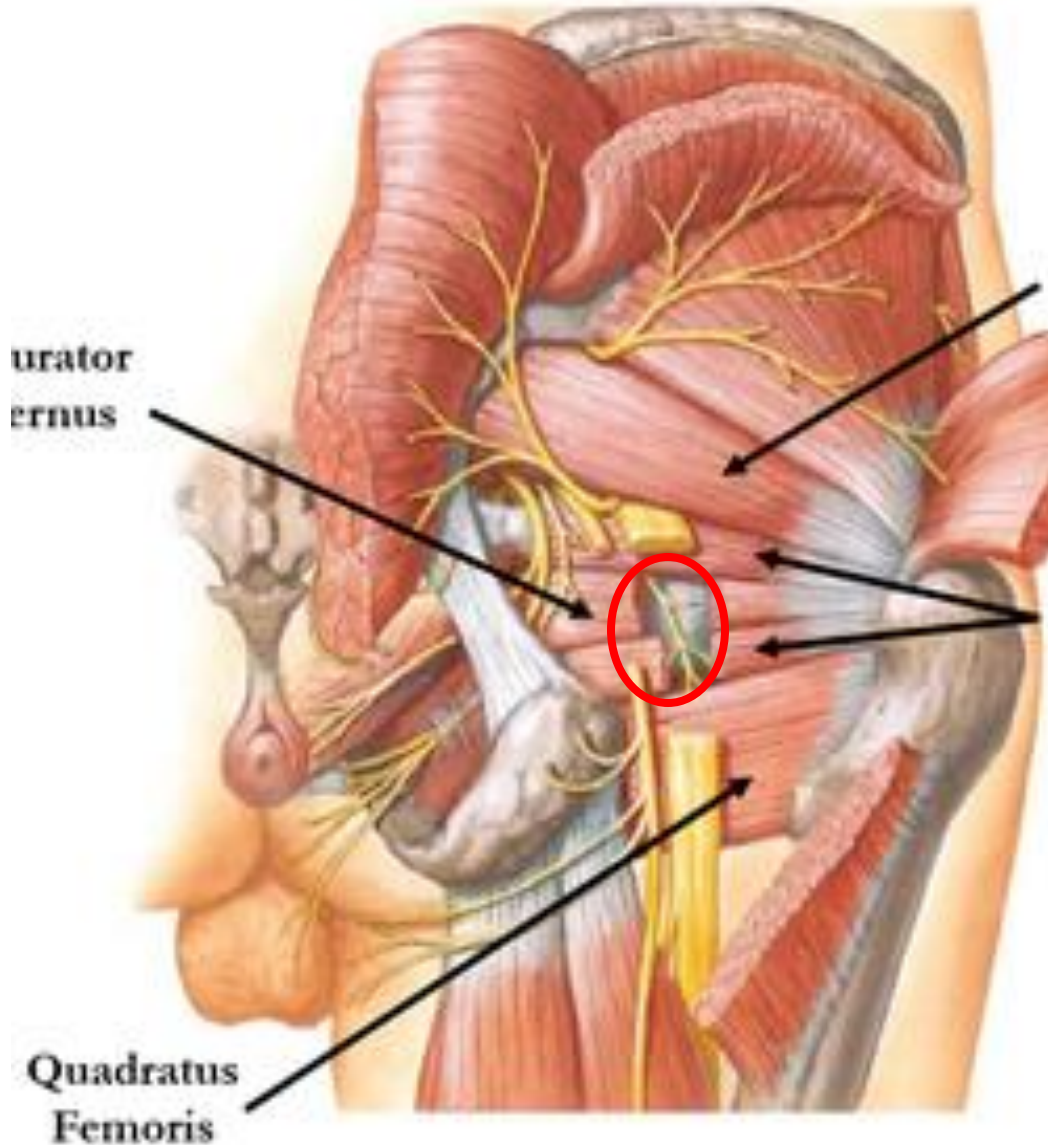
SUPPLIES-

Skin of posteroinferior quadrant of gluteal region



Perforating cutaneous nerve (S2,3) (perforates the sacrotuberous ligament)

4. Nerve to Quadratus Femoris (L4,L5,S1- ventral division)

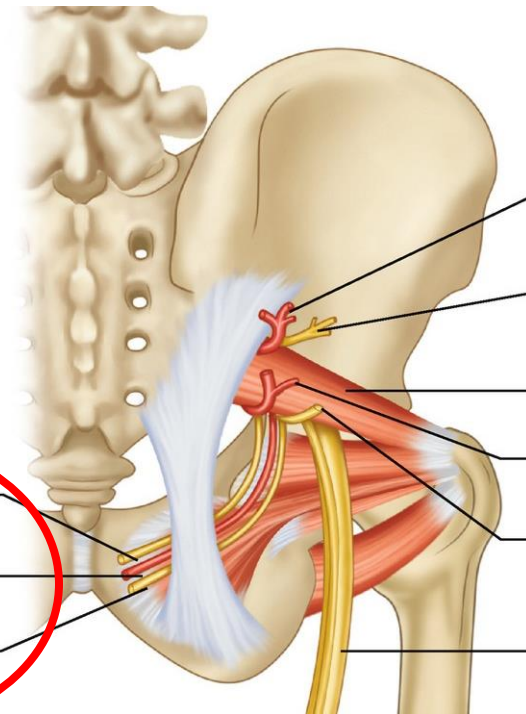
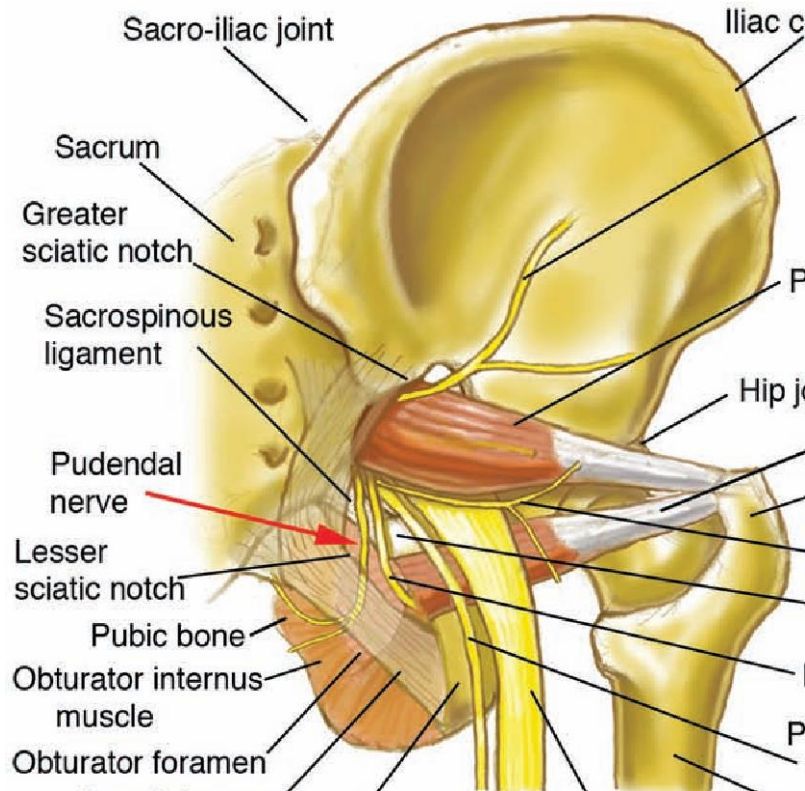


- Enters through Greater sciatic foramen
- Below Piriformis
- Runs deep to sciatic nerve, obturator internus & gemilli

SUPPLIES:

1. Quadratus femoris
2. Inferior gemellus
3. Hip joint

5. Nerve to Obturator Internus (L5,S1,S2 – ventral division)



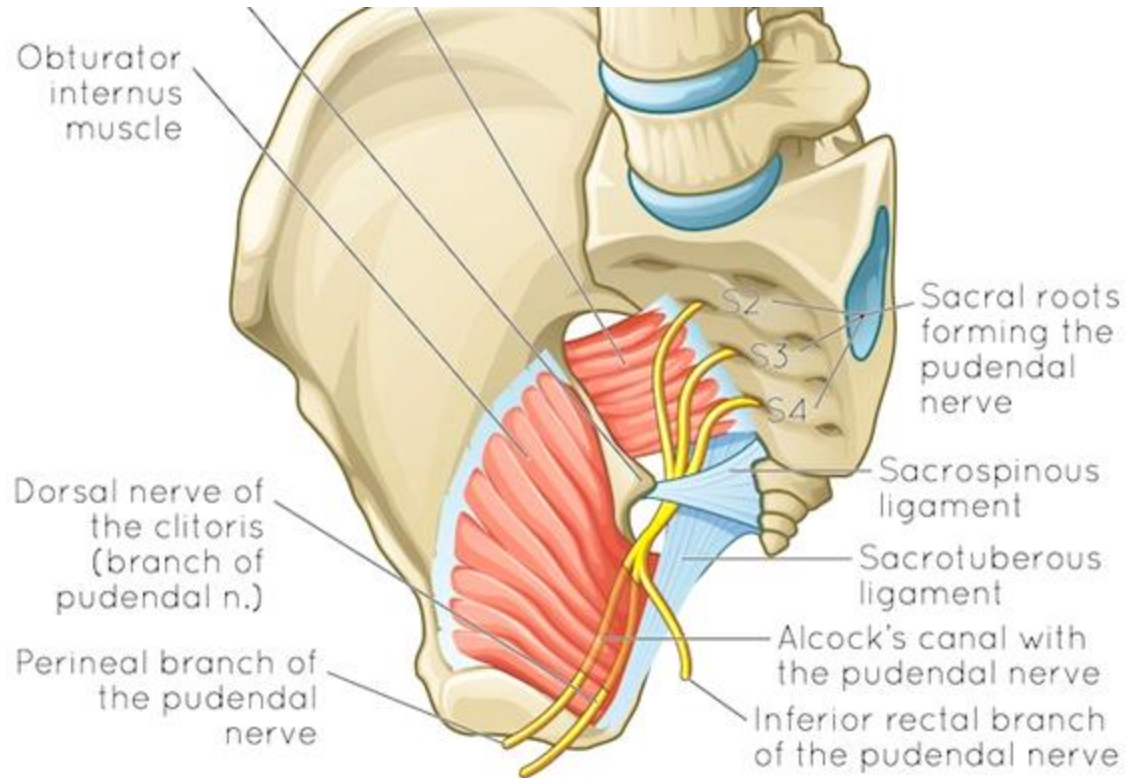
- Enters through greater sciatic notch
- Below piriformis
- Crosses ischial spine lateral to internal pudendal vessels
- Reenters pelvis through lesser sciatic foramen

SUPPLIES:

- Obturator internus
- Gemellus superior

PIN
structures

6. Pudendal nerve (S2,S3,S4 – ventral division)



Only small part seen in gluteal region

- Enters through greater sciatic foramen
- Below piriformis
- **Crosses apex of sacrospinous ligament**
- **Medial to internal pudendal vessels**
- **Passes through lesser sciatic foramen**
- **Enters pudendal canal in ischioanal fossa**

SUPPLIES

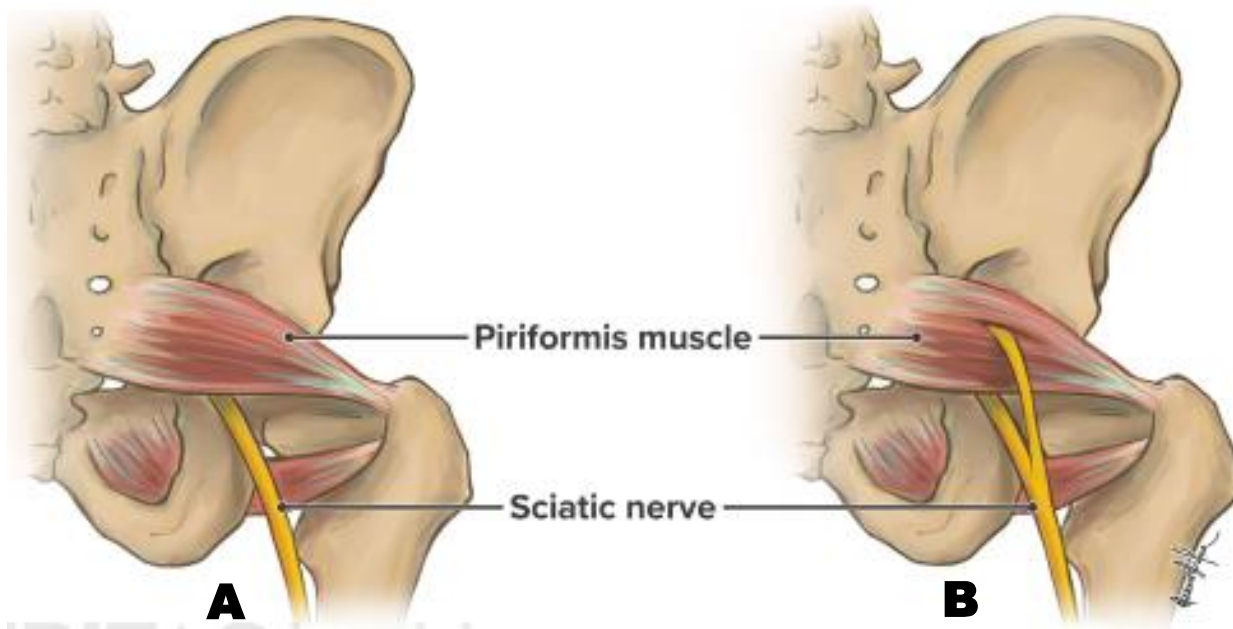
No structure in gluteal region

- Supplies external anal sphincter & structures in perineum

PIN
structures

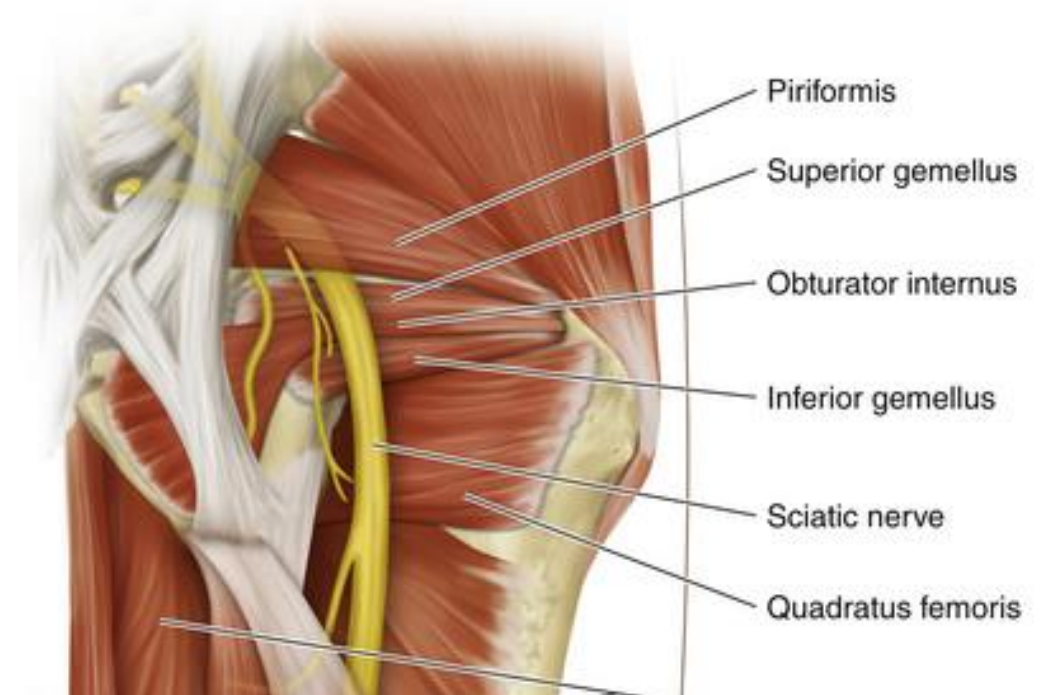
7. Sciatic nerve (in the pelvis)

(L4,L5,S1,S2,S3 – Both dorsal & ventral divisions)

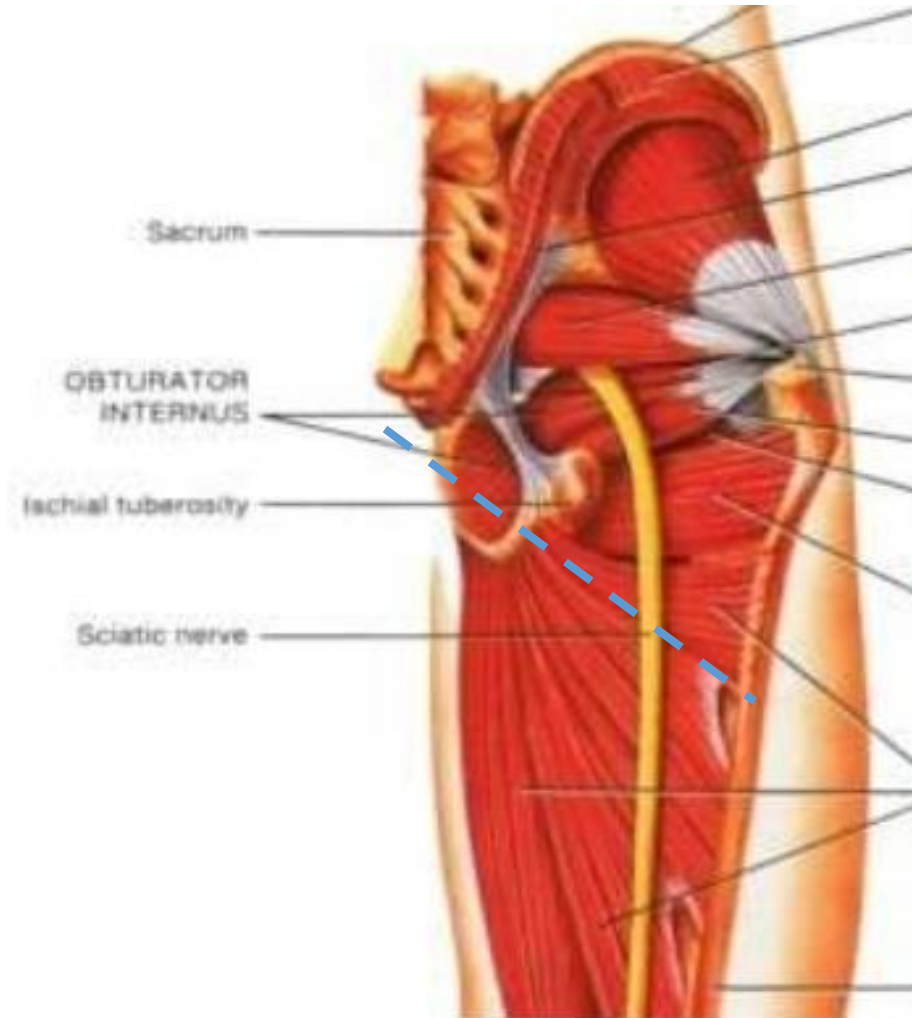


- Begins in pelvis
- **Thickest nerve in the body (2 cm wide)**
- Lies in front of piriformis

- Largest branch of sciatic plexus
- Made up of 2 parts –
 - **tibial part**
(L4,L5,S1,S2,S3 – ventral divisions)
 - **Common peroneal part**
(L4,L5,S1,S2 – dorsal divisions)



7. Sciatic nerve (in the gluteal region) (L4,L5,S1,S2,S3 – Both dorsal & ventral divisions)



- Enters through greater sciatic foramen
- Below piriformis
- **Runs inferiorly between greater trochanter & ischial tuberosity**
- Enters back of thigh beneath lower border of gluteus maximus

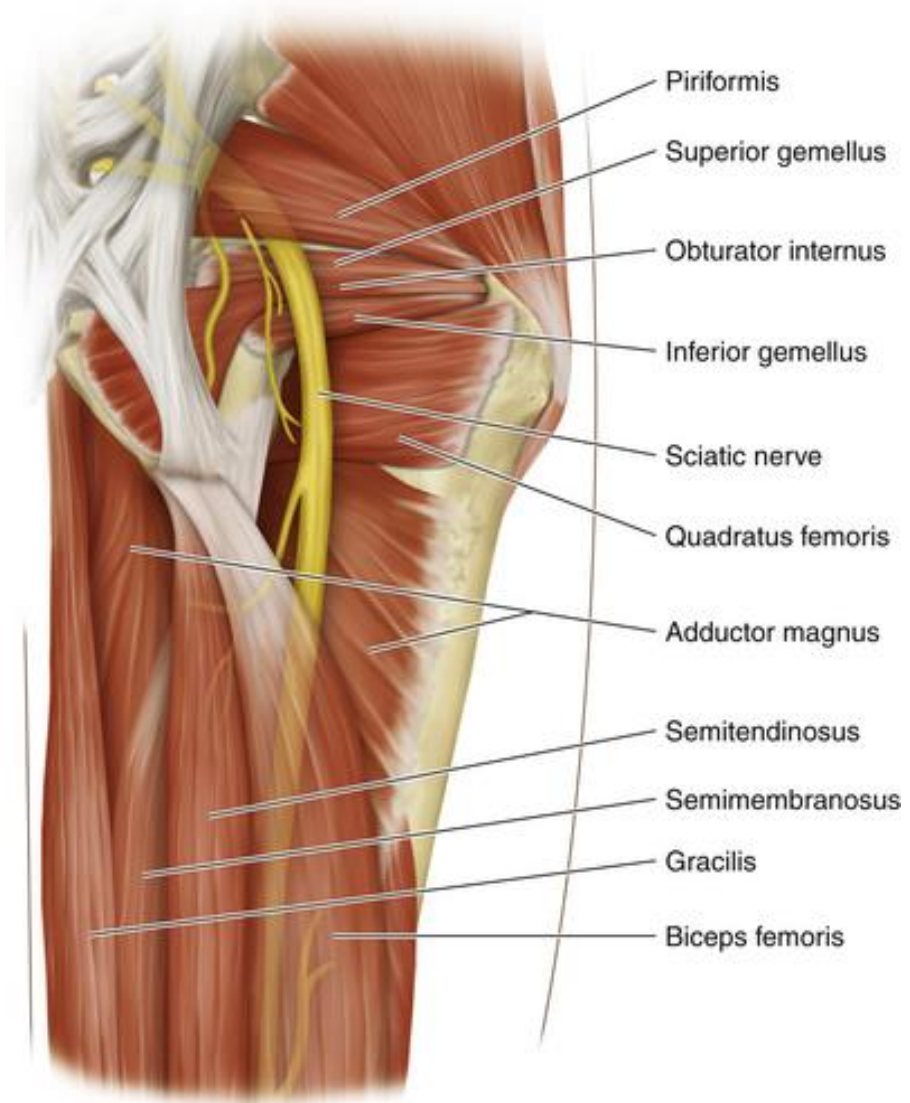
SUPPLIES:

No muscle in gluteal region

Supplies muscles in back of thigh & all the compartments of leg And foot through its branches

sciatic nerve contd....

Relations in gluteal region



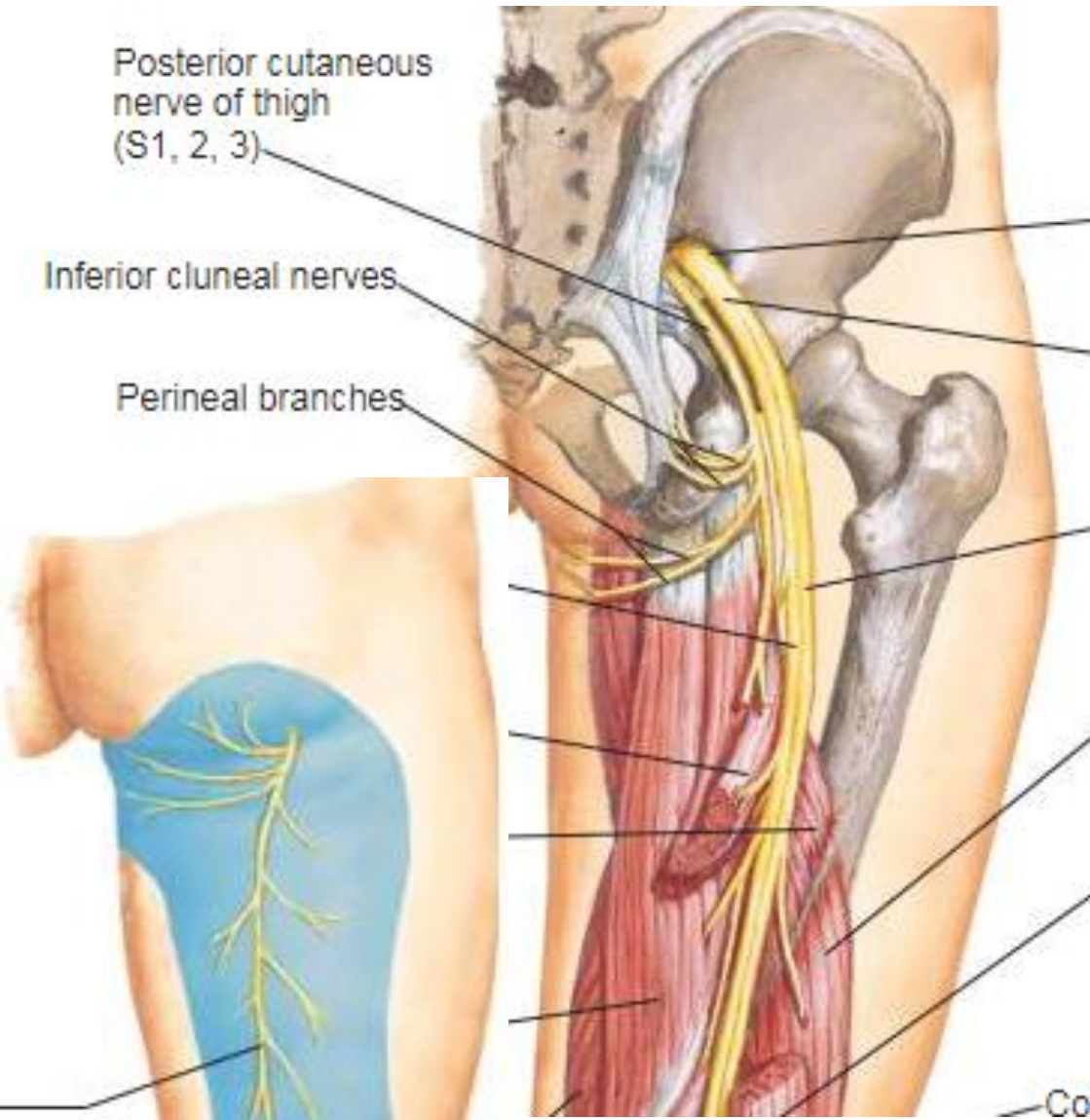
- **SUPERFICIAL –**
 - Gluteus maximus

- **DEEP –**
 - Body of ischium
 - Tendon of obturator internus with 2 gemilli
 - Quadratus femoris, obturator externus
 - Posterior surface of capsule of hip joint
 - Upper transverse fibres of adductor magnus

- **MEDIAL-**
 - Inferior gluteal nerves & vessels

8. Posterior cutaneous nerve of thigh

(S1,S2,S3 – both dorsal & ventral divisions)



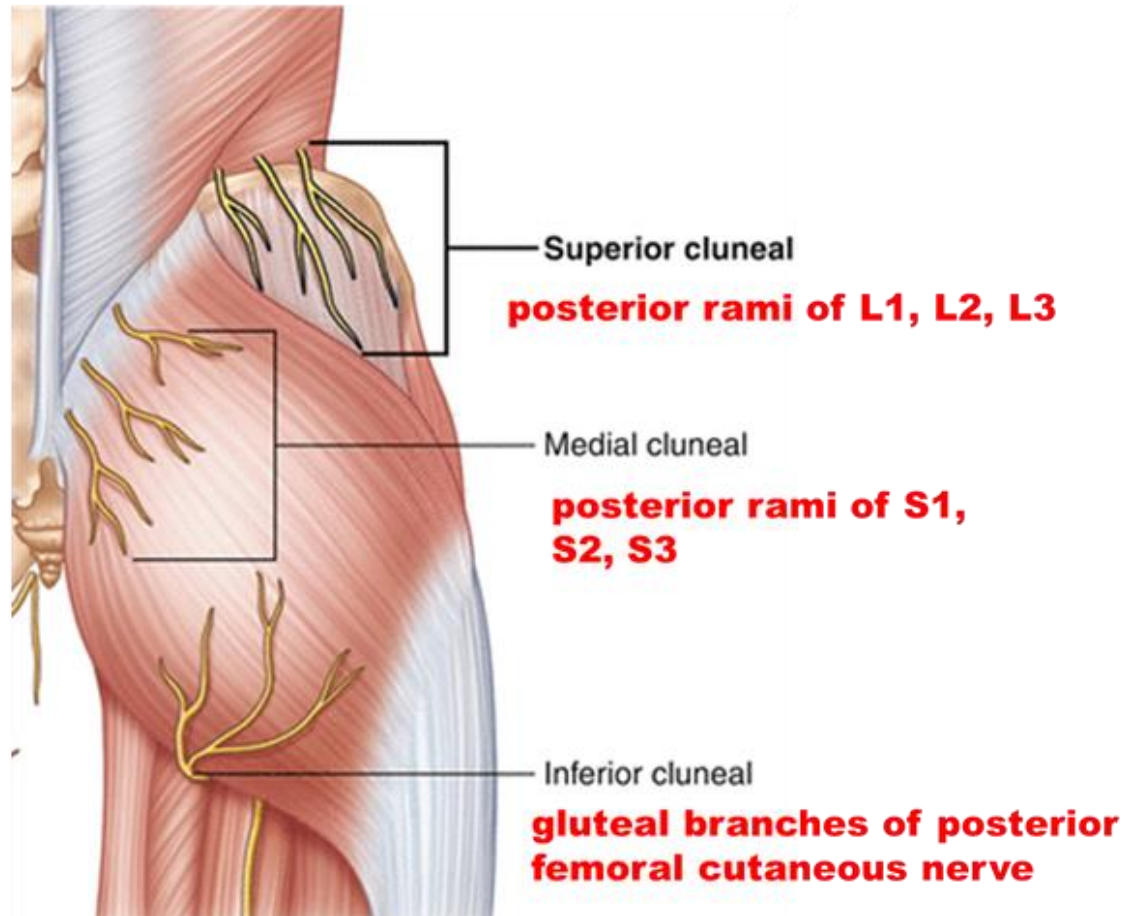
- Enters through greater sciatic foramen
- Below piriformis

- **Runs downwards medial to sciatic nerve**
- **Continues in back of thigh deep to deep fascia**

BRANCHES:

- Perineal branch- crosses ischial tuberosity, enters urogenital region-supplies anterior 2/3rd of scrotum/ labium majus (posterior scrotal nerves)
- Gluteal branches – wind around lower border of gluteus maximus – supply posteroinferior quadrant of skin of gluteal region

What are Cluneal nerves ?



- are cutaneous nerves supplying gluteal region
- **Compression of these nerves may cause entrapment neuropathy**
- **Entrapment neuropathy of Superior & medial cluneal –presents as lower back pain**
- Patients with **inferior cluneal nerve (ICN)** entrapment complain of a burning, tingling, or numbness sensation along the inferior and medial aspects of the buttocks

Arteries in the gluteal region

(branches from anterior or posterior divisions of internal iliac artery)

1. Superior gluteal artery
2. Inferior gluteal artery
3. Internal pudendal artery

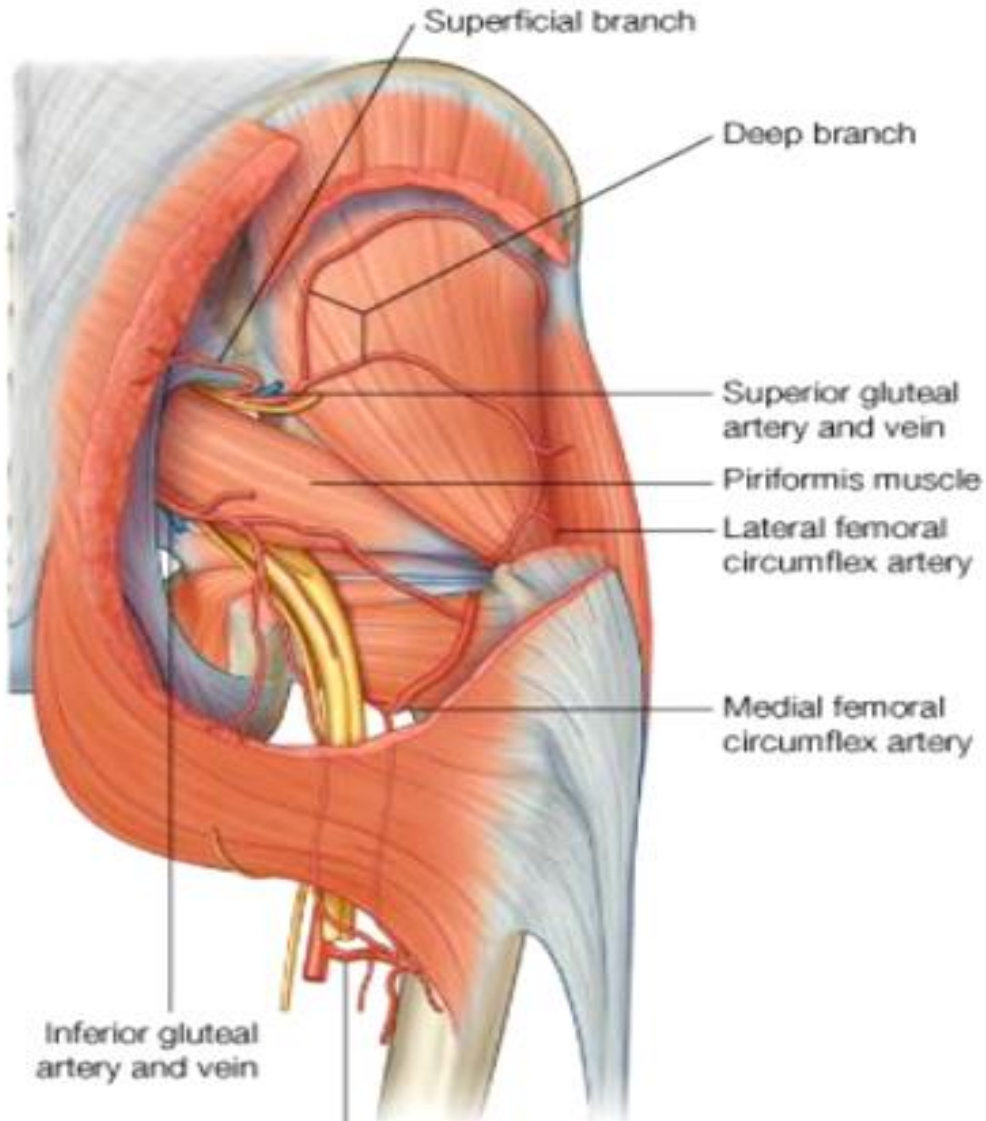
Anastomosis in gluteal region

Trochanteric anastomoses

Cruciate anastomoses

1. Superior Gluteal artery

(Branch of posterior division of internal iliac artery)



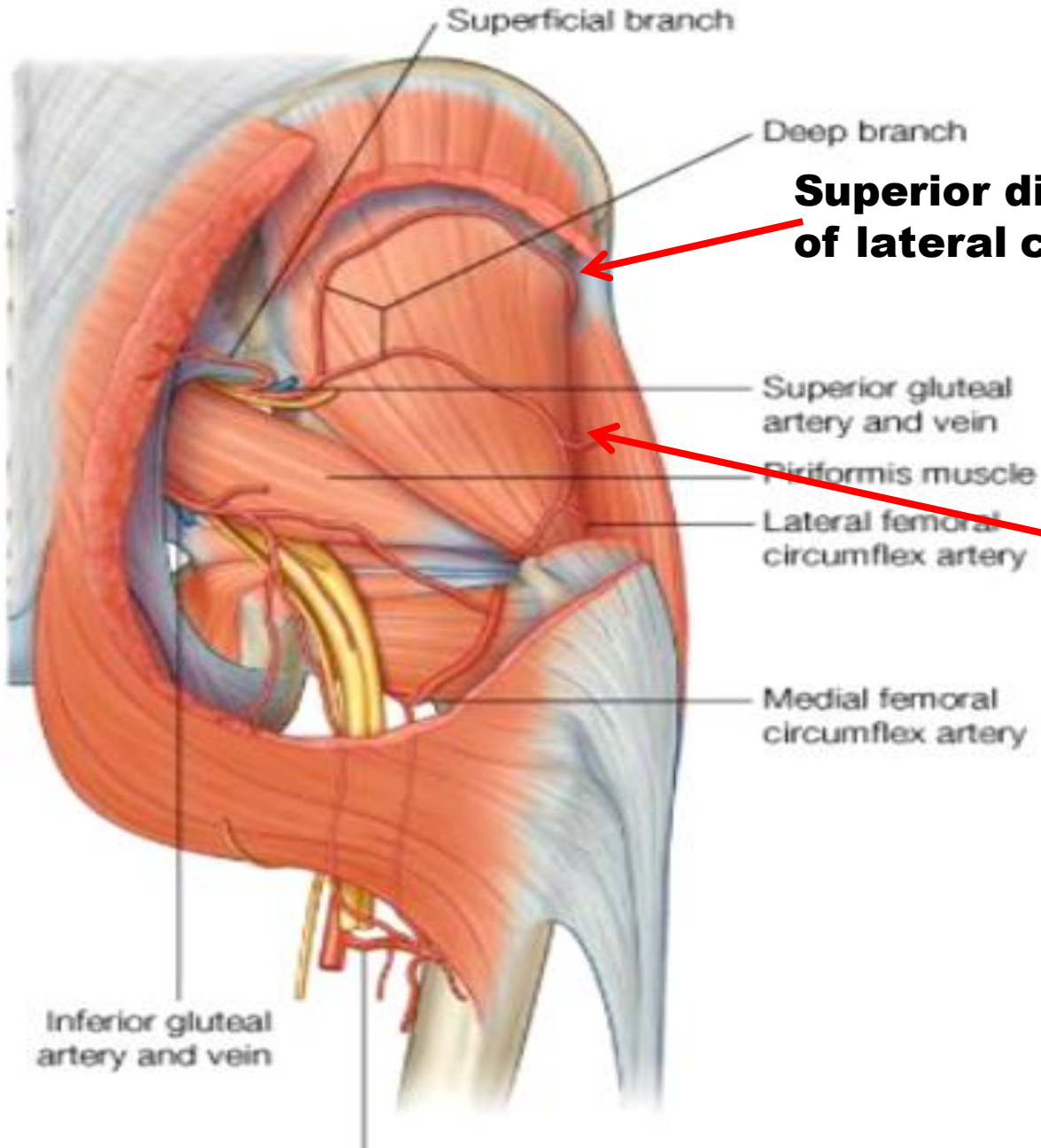
- Enters through greater sciatic notch
- Above piriformis
- Divides in foramen –
 - Superficial branch
 - Deep branch

SUPPLIES:

Superficial Branch – Gluteus maximus

Deep Branch – divides into superior & inferior divisions, they run along anterior & inferior gluteal lines between medius & minimus

Superior gluteal artery contd....

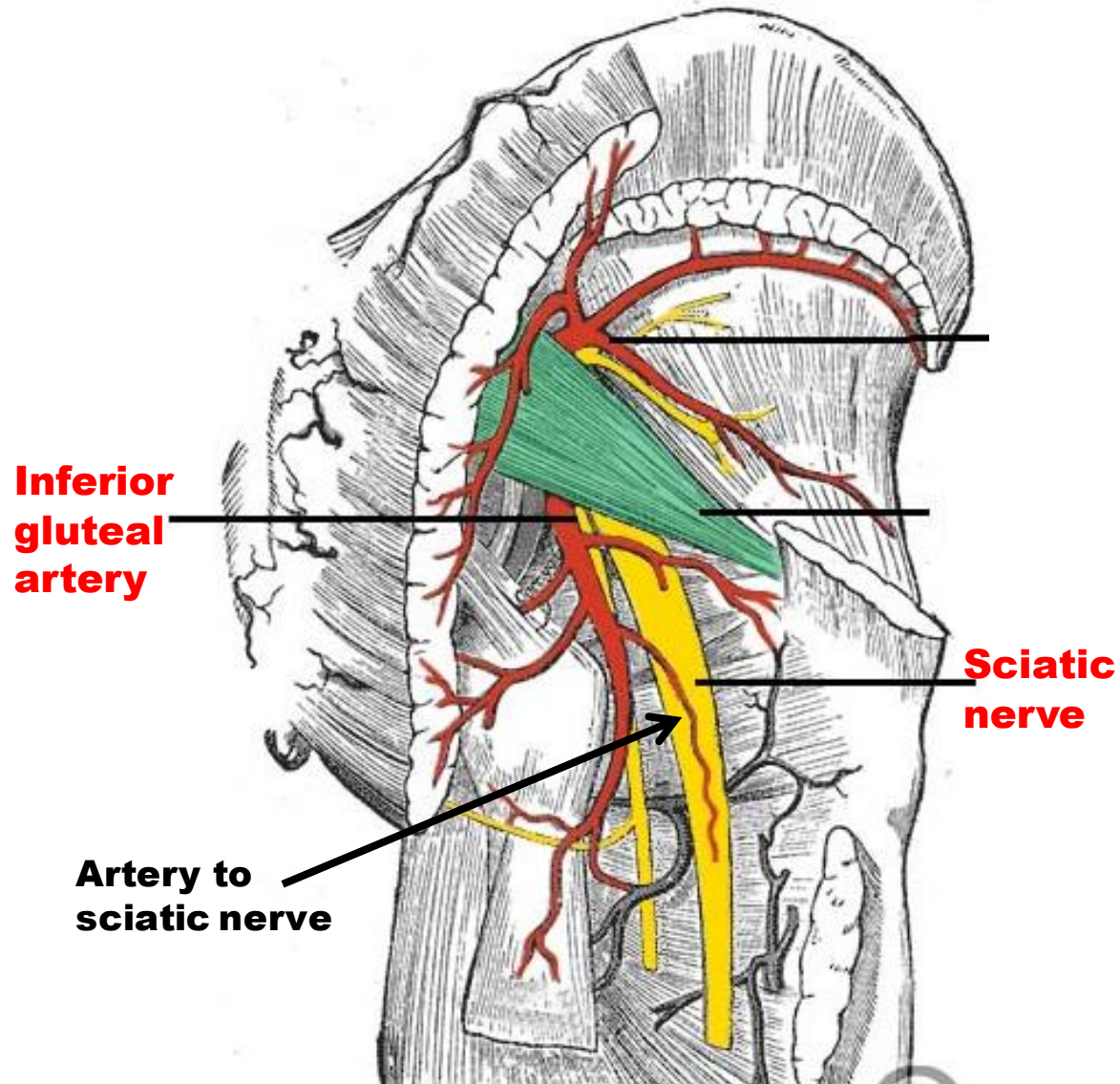


Superior division anastomoses with ascending branch of lateral circumflex femoral artery at ASIS

Inferior division takes part in trochanteric anastomoses

2. Inferior Gluteal artery

(Branch of anterior division of internal iliac artery)

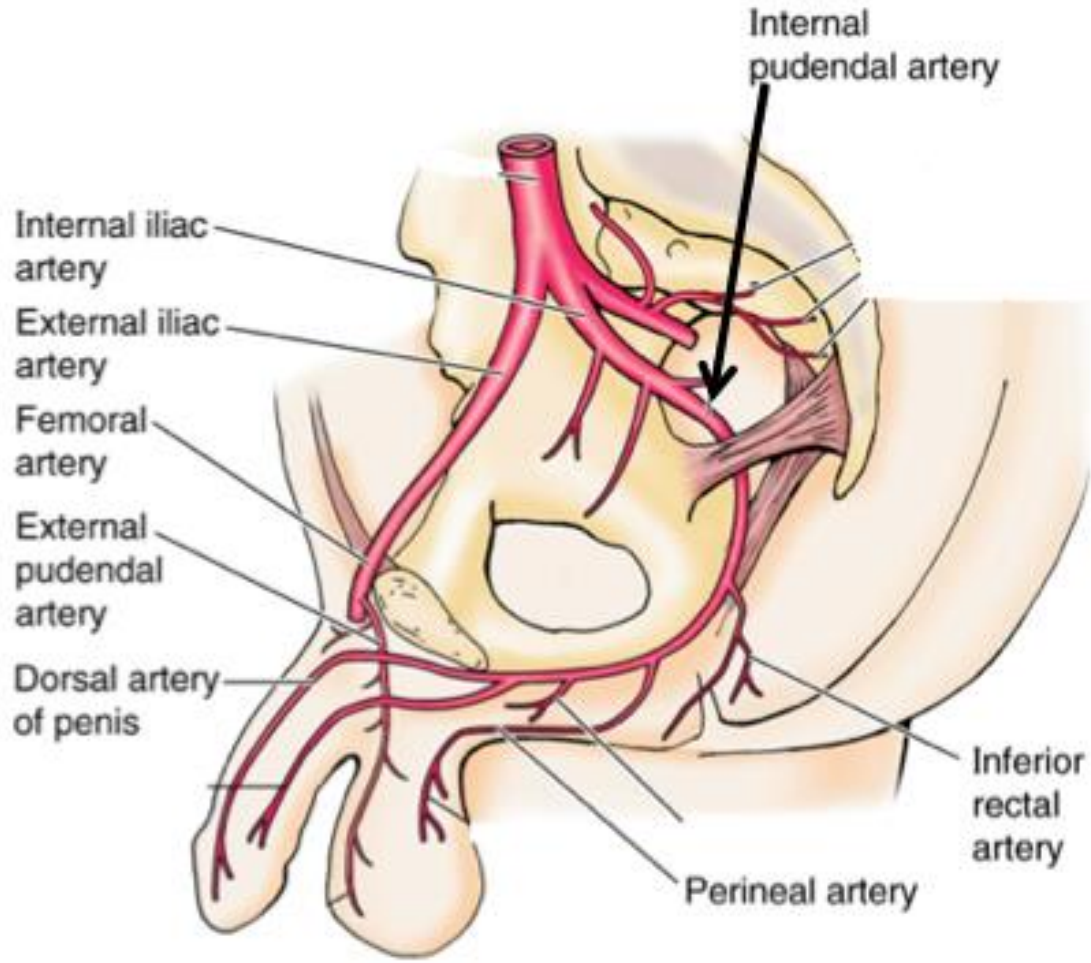


- Enters through greater sciatic foramen
- Below piriformis

SUPPLIES:

1. Muscular branches- Gluteus maximus & other muscles below piriformis
2. Cutaneous branches- skin of gluteal region
3. Articular branch- hip joint
4. Anastomotic branches- trochanteric & cruciate anastomosis
5. Artery to sciatic nerve-represents axis artery may be very large
6. Coccygeal branch – area over coccyx

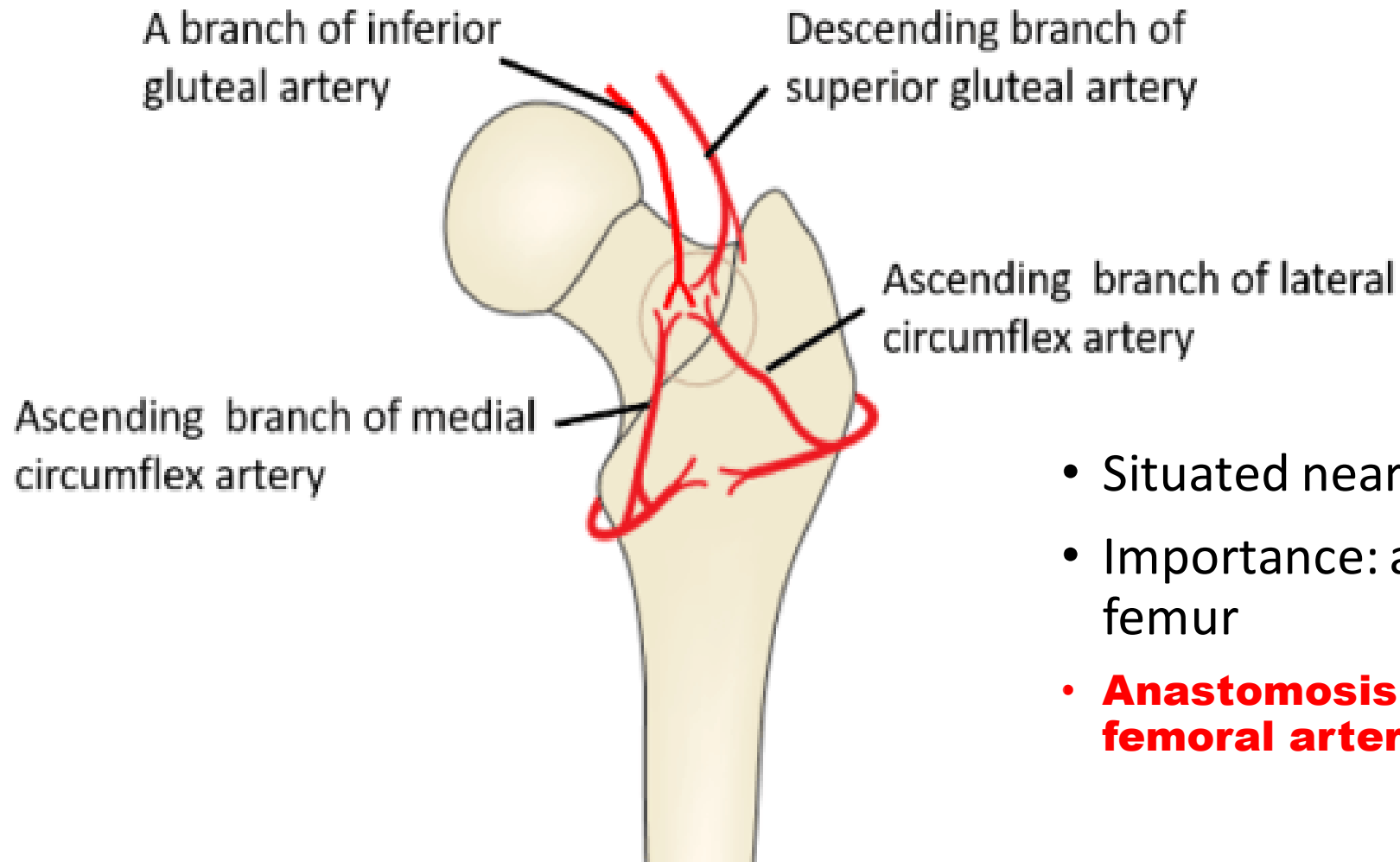
3. Internal pudendal artery (Branch of anterior division of internal iliac artery)



- Enters through greater sciatic notch
- Has short course in gluteal region
- **Crosses ischial spine, passes through lesser sciatic foramen & enters ischioanal fossa in pudendal canal**

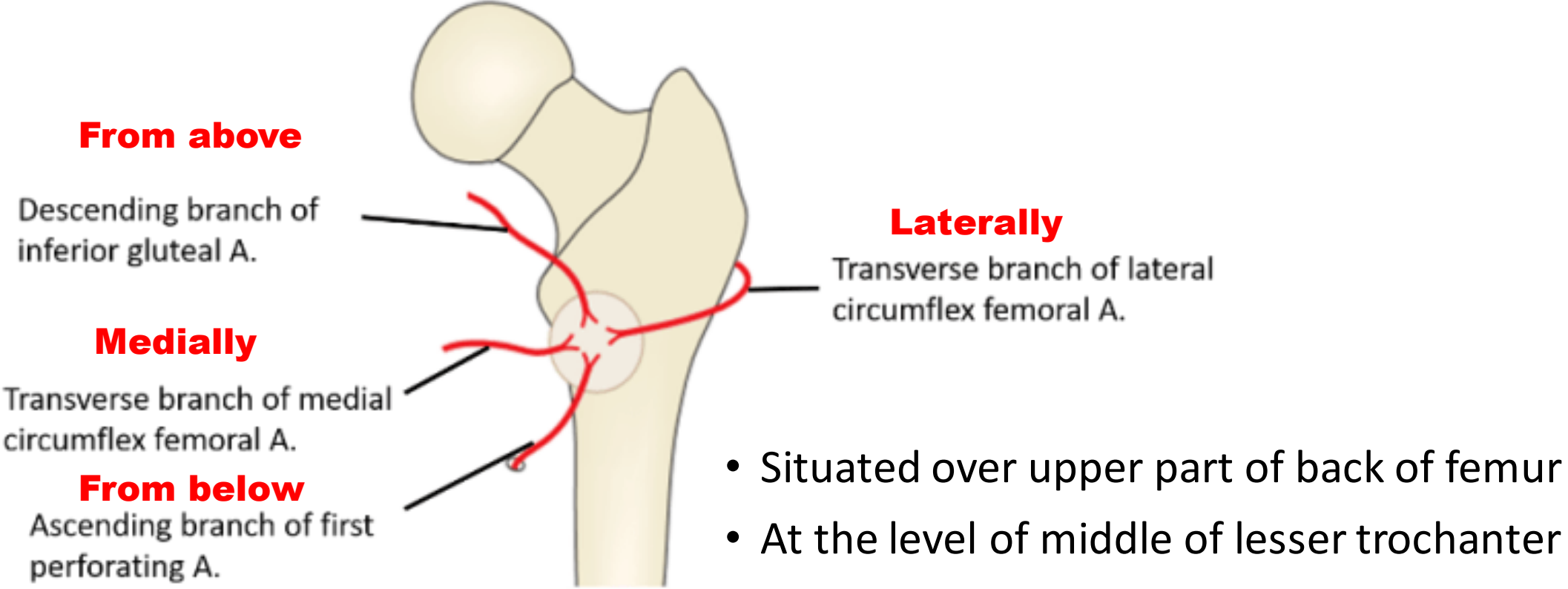
PIN
structures

Trochanteric Anastomosis



- Situated near trochanteric fossa
- Importance: arterial supply to head of femur
- **Anastomosis between –internal iliac & femoral arteries**

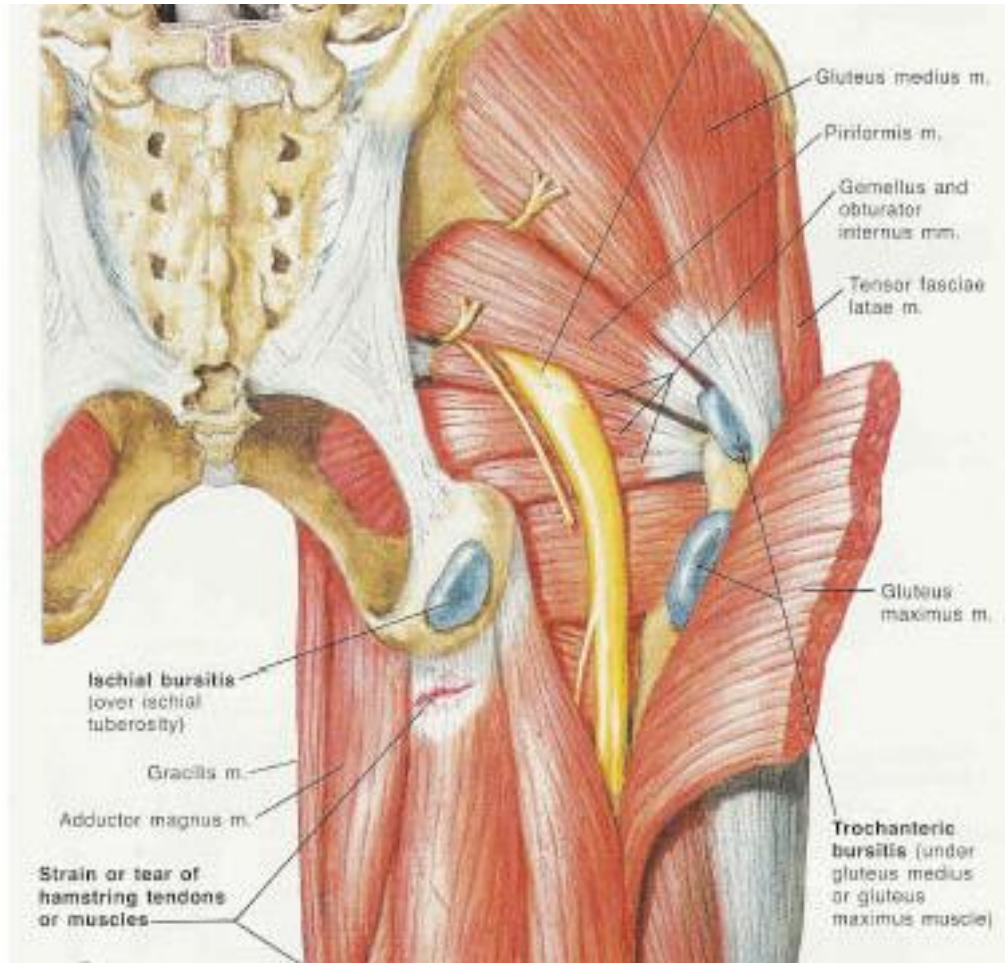
Cruciate Anastomosis



Veins and Lymphatics of the gluteal region

- **Veins**
- Inferior and superior gluteal veins follow the inferior and superior gluteal arteries into the pelvis where they join the pelvic plexus of veins. Peripherally, the veins anastomose with superficial gluteal veins, which ultimately drain anteriorly into the femoral vein
- **Lymphatics**
- Deep lymphatic vessels of the gluteal region accompany the blood vessels into the pelvic cavity and connect with internal iliac nodes.
- Superficial lymphatics drain into the superficial inguinal nodes on the anterior aspect of the thigh.

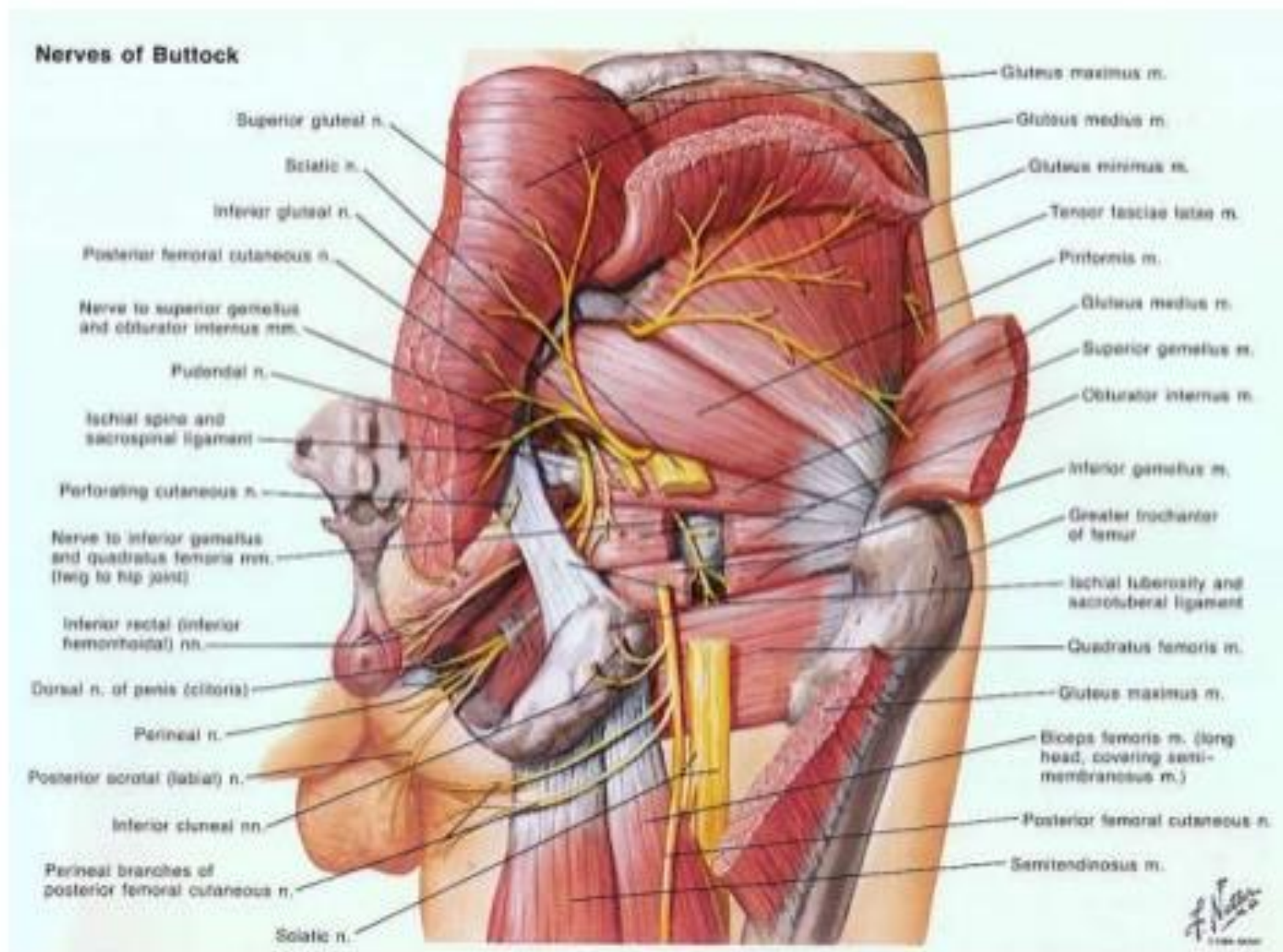
Bursae deep to gluteus maximus



1. Trochanteric bursa between gluteus maximus & greater trochanter
2. Bursa between gluteus maximus & ischial tuberosity
3. Bursa between gluteus maximus and vastus lateralis

Structures undercover of gluteus maximus

- Muscles
- Vessels
- Nerves
- Bones & Joints
- Ligaments
- Bursae



Muscles under cover of gluteus maximus

- Gluteus Medius,
- Gluteus Minimus,
- Reflected Head of the Rectus Femoris,
- Obturator Internus with 2 Gemelli,
- Obturator Externus,
- Piriformis,
- Quadratus Femoris,
- origin of the four hamstring muscles from the ischial tuberosity
- Insertion of the upper fibres of the adductor magnus,

Vessels under cover of gluteus maximus

- superior gluteal vessels,
- inferior gluteal vessels,
- internal pudendal vessels,
- ascending branch of the medial circumflex femoral artery,
- trochanteric anastomoses,
- cruciate anastomoses,
- first perforating artery

Nerves under cover of gluteus maximus

- Superior gluteal nerve (L4,L5,S1),
- Inferior gluteus nerve (L5,S1, S2),
- Pudendal Nerve (S2,S3,S4),
- Posterior Cutaneous Nerve of thigh (S1,S2,S3),
- Perforating Cutaneous Nerve (S2,S3),
- Sciatic Nerve (L4,L5,S1,S2,S3),
- Nerve to Quadratus Femoris (L4,L5,S1),
- Nerve to Obturator Internus (L5,S1,S2)

Bones, joints & Ligaments under gluteus maximus

- Bones & Joints
 - Ilium,
 - Ischium with the ischial tuberosity,
 - hip joint,
 - sacroiliac joint,
 - sacrum and coccyx,
 - upper end of the femur with the greater trochanter
- Ligaments
 - Sacrotuberous,
 - Sacrospinous,
 - ischiofemoral

Bursae under cover of gluteus maximus

- trochanteric bursa of the glut max,
- bursa above the ischial tuberosity,
- bursa between the gluteus maximus and the vastus lateralis

Structures passing out of pelvis

Exit ONLY

Greater Sciatic Foramen

Piriformis muscle
Sup. Gluteal a./v./n.
Inf. Gluteal a./v./n.
Nerve to quadratus femoris
Sciatic nerve
Posterior cutaneous nerve of thigh

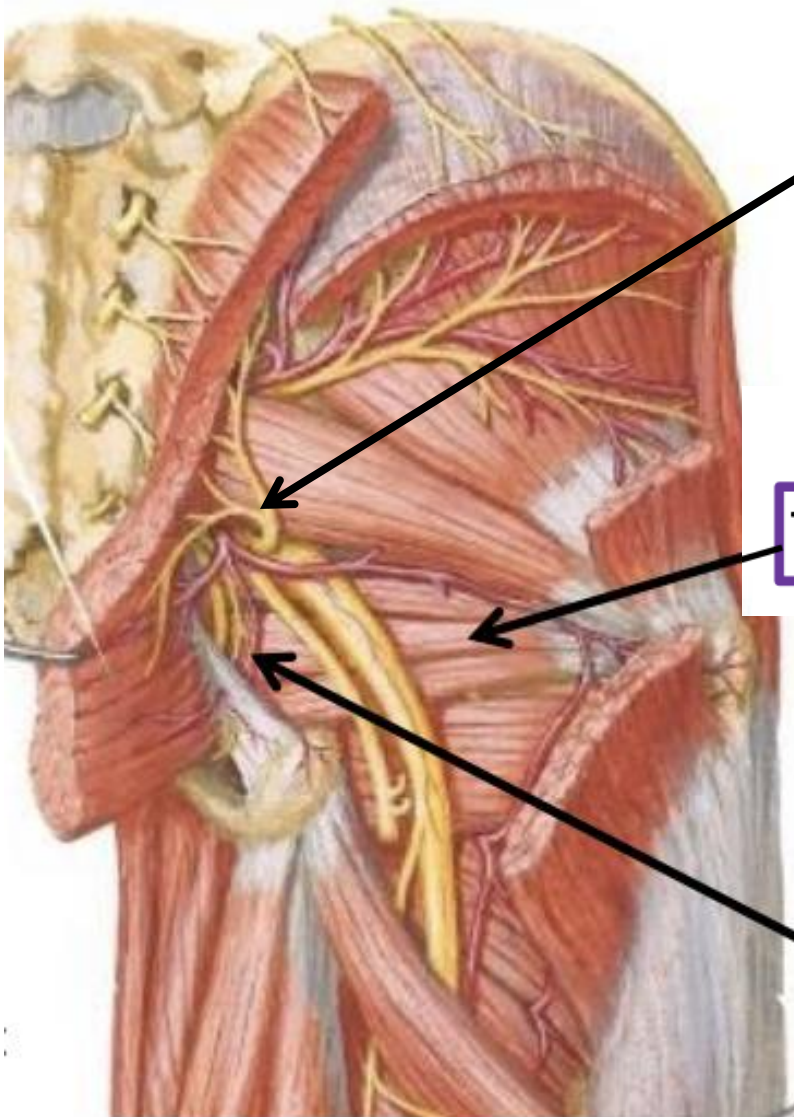
Exit ONLY

Lesser Sciatic Foramen

Tendon of Obturator Internus m.

EXIT Greater Sciatic Foramen
& ENTER Lesser Sciatic Foramen

Pudendal nerve
Internal pudendal a./v.
Nerve to obturator internus



ABOVE PIRIFORMIS: ??

BELOW PIRIFORMIS: ??

Fate of vessels & nerves that enter the gluteal region from pelvis

I. Remain in the gluteal region

- I. Gluteal vessels & nerves

II. Descend from gluteal region into back of thigh

- I. Sciatic nerve
- II. Posterior cutaneous nerve of thigh
- III. Branches of inferior gluteal vessels

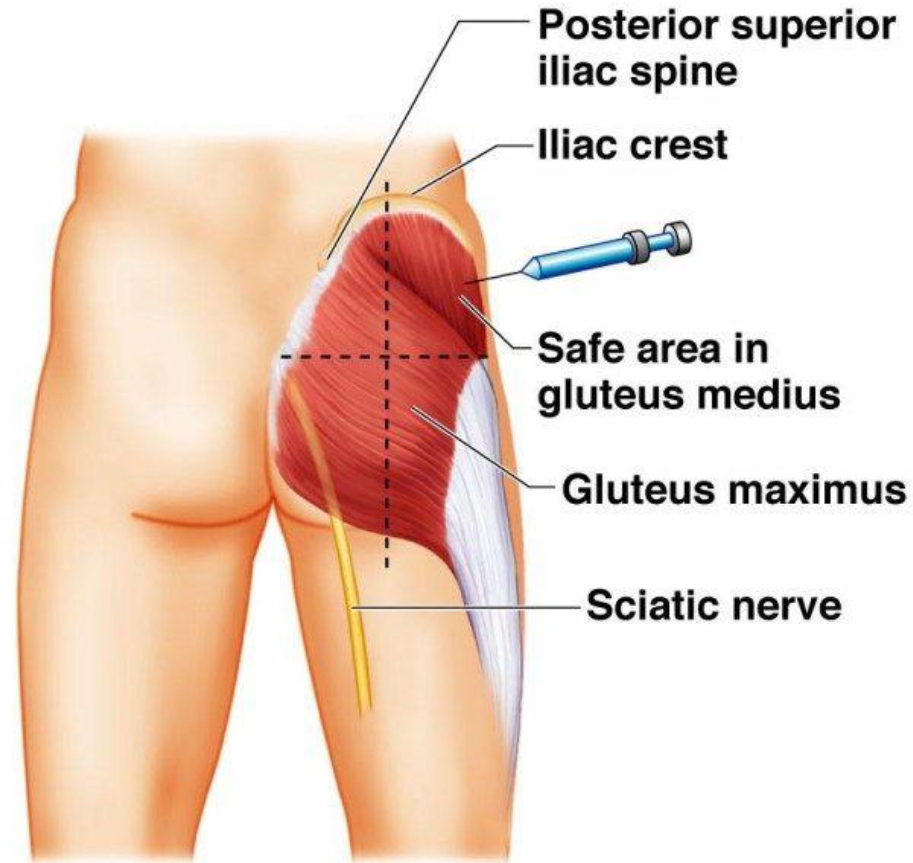
III. Turn forwards through lesser sciatic foramen into perineum

PIN structures (curve over posterior surface of ischial spine & sacrospinous ligament)

- I. Pudendal nerve
- II. Internal pudendal vessels
- III. Nerve to obturator internus

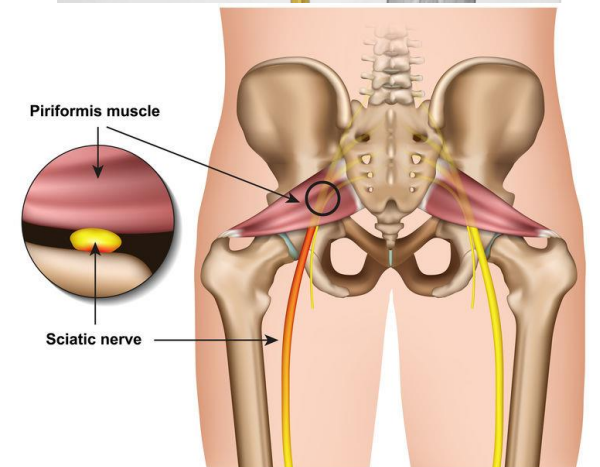
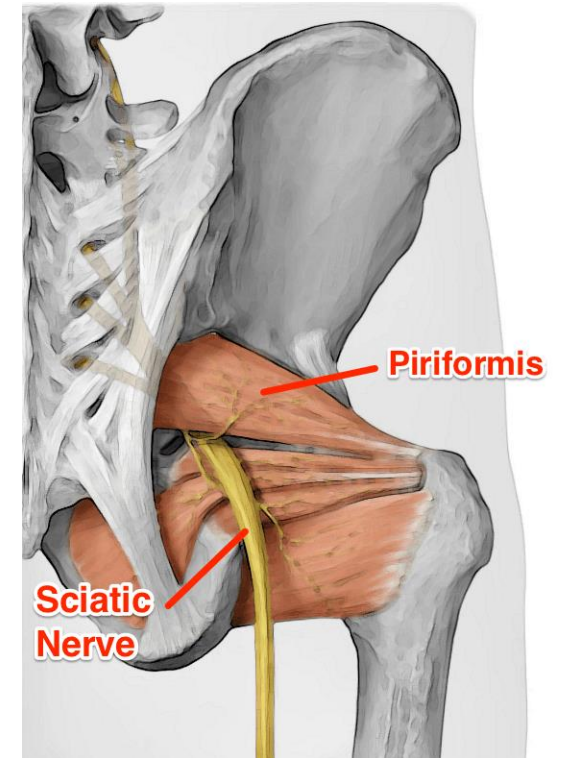
Applied

- I/m injection is given in superolateral quadrant of gluteal region to avoid injury to nerves



Piriformis Syndrome

- **Piriformis syndrome** is a painful condition that develops due to irritation or compression of the sciatic nerve near the piriformis muscle.
- Symptoms include pain, tingling or numbness in the buttocks and down the leg, which may worsen after sitting for a long time, climbing stairs, walking or running.



CASE REPORT

- A 68-year-old male patient presented with difficulty in walking, he had weakness of his left leg and foot as well as severe aching and electrical-shooting pain along his left posterolateral thigh, leg, and foot of 3-month duration.
- Three months prior, he had undergone an appendectomy.
- He received an intramuscular injection in the gluteal region postoperatively for pain control.
- While receiving the IM injection of the analgesic medication in his left buttock, a severe electric shock-like pain developed. The nurse reassured him that it would be okay.
- 3 hours later the patient could not walk due to weakness in his left foot. Severe aching and electricity-like pain developed in his left posterolateral thigh, leg, and foot.

Could the pain be due to accidental injury to any structure while administering i/m injection?

Which structure may have been injured?

Why?

Thank You