

# *Otosclerosis*

Dr H. P. Singh

Additional Professor

Department of Otorhinolaryngology & Head-Neck Surgery

# Disclaimer

This presentation is for educational purposes only not for commercial activity.

# Background

primary metabolic bone disease of the otic capsule and ossicles

- It causes fixation of the ossicles (stapes)
- It results in conductive or mixed hearing loss.
- It is genetically-mediated via autosomal dominant transmission

# Epidemiology

## **Race**

## **incidence of microscopic otosclerosis**

Caucasian

10%

Asian

5%

African American

1%

Native American

0%

# Epidemiology

- Sex variation (M:F=1:2.5)
  - Women more commonly seek medical attention for hearing loss secondary to Otosclerosis.

# Epidemiology

- Age
  - The incidence of otosclerosis increases with age.
  - The most common age group presenting with hearing loss from otosclerosis is 15-45 years,
  - however it has been reported to manifest as early as 7 years and as late as the mid 50s.

# Etiology

- Many theories have been proposed-
  - hereditary, 54% of patients present with family history
  - endocrine, women with pregnancy- hearing gets worse
  - metabolic,
  - infectious,
  - vascular,
  - Autoimmune.
- None have been proven.
- Hormonal factors have been suggested to play a role in otosclerosis based on the observation that pregnancy sometimes accelerates the progression of the disease.

# Pathophysiology

- Otosclerosis (otospongiosis) is an osseous dyscrasia
- limited to the temporal bone
- characterized by resorption and formation of new bone in the area of the ossicles and otic capsule.

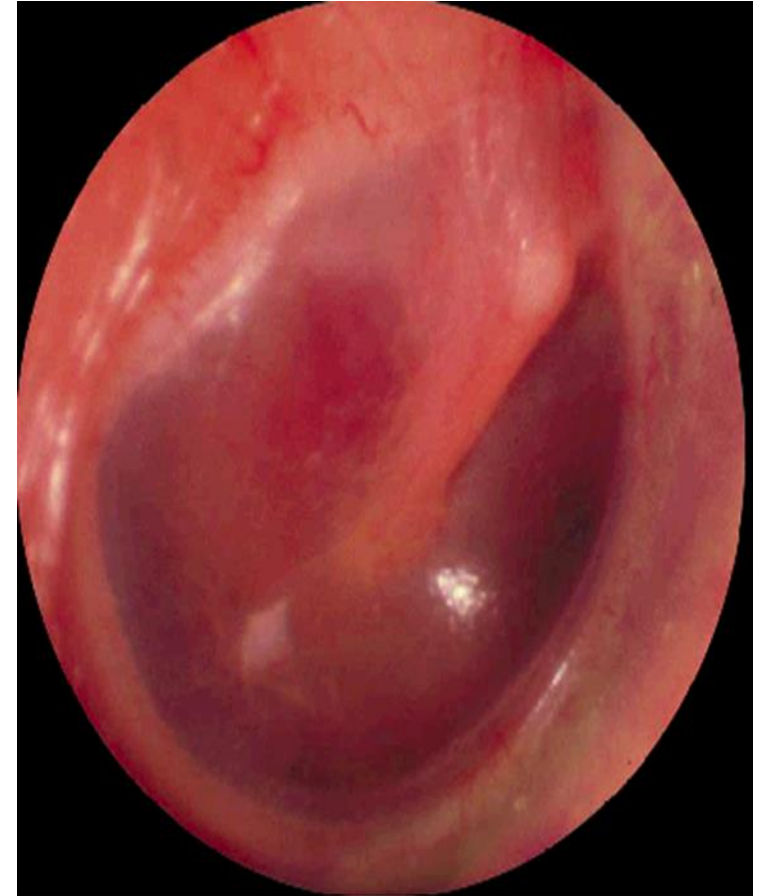

# Pathophysiology

- The most common site of involvement is the anterior oval window near the fissula ante fenestrum.
- When both the anterior and posterior ends of the footplate are involved it is termed “bipolar” involvement or fixation (if the footplate is immobile).
- If only the footplate is involved, it is sometimes referred to as a “**stapedial otosclerosis**”.
- When the entire footplate and annular ligament are involved it is known as an obliterated footplate or oblitative otosclerosis.
- The round window is involved in approximately 30% to 50% of cases

# Pathophysiology

- otosclerosis has two main forms:
  - early or spongiotic phase (otospongiosis)
    - The early phase is characterized by multiple active cell groups including osteocytes, osteoblasts, and histiocytes. It develops a spongy appearance because of vascular dilation secondary to osteocyte resorption of bone surrounding blood vessels. This can be seen grossly as red hue behind the tympanic membrane termed “Schwartz's sign”



# Pathophysiology

- late or sclerotic phase
  - dense sclerotic bone forms in the areas of previous resorption. Both the sclerotic and spongiotic as well as intermediate phases may be present at the same time. Otosclerotic foci always begin in endochondral bone but may progress to involve endosteal and periosteal layers and even enter into the membranous labyrinth.

# Pathophysiology

- Microscopically, a focus of active otosclerosis reveals finger projections of disorganized bone, rich in osteocytes particularly at the leading edge. In the center of the focus, multinucleated osteocytes are often present

# Diagnosis

- Slowly progressive, bilateral (80%), asymmetric, conductive hearing loss
  - Tinnitus is associated with 75% patients
  - The age of onset of hearing loss is young
  - History of significant ear infections makes the diagnosis of otosclerosis less likely.
  - 25% of patients present with some vestibular complaints

# Diagnosis

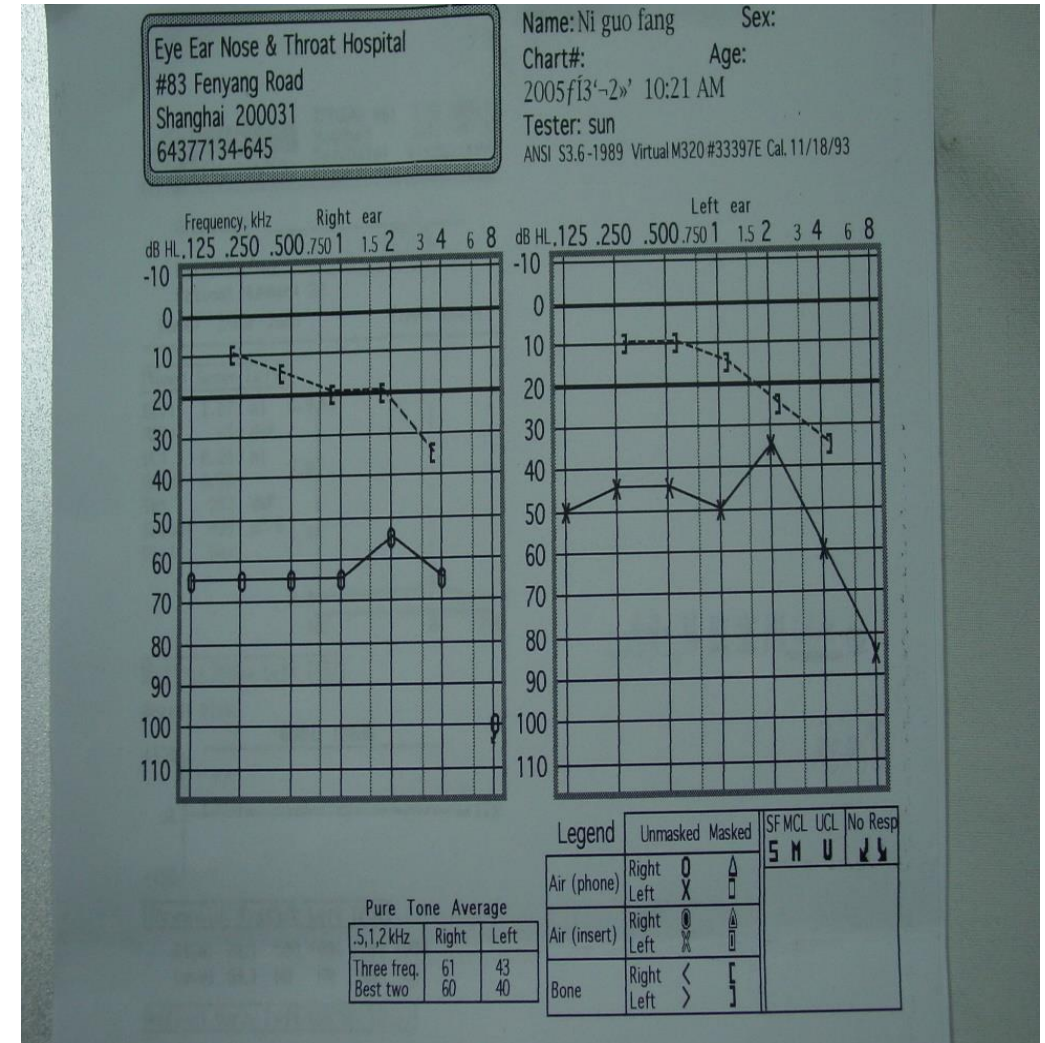
- low-volume speech.
  - conductive nature of their hearing loss, they perceive their voice as louder than it actually is.
- Paracusis of Willis
  - It occurs because the CHL reduces the volume of the background noise,
- Two-thirds of patients will report a family history of hearing loss.
- Women with pregnancy worsen her hearing

# Physical examination

- TM appears normal in the majority of patients
- Schwartze sign is observed in 10% of patients).
- Rinne test: negative
  - Early in the disease, low frequency CHL will predominate resulting in a negative Rinne test with the 256-Hz only.
  - As progression occurs, the 512 and then the 1,024-Hz TF will become negative.
- Weber test: laterization to poor HL
- Schwabach test: prolonged bone conduction
- Gelle test: negative

# Tests-

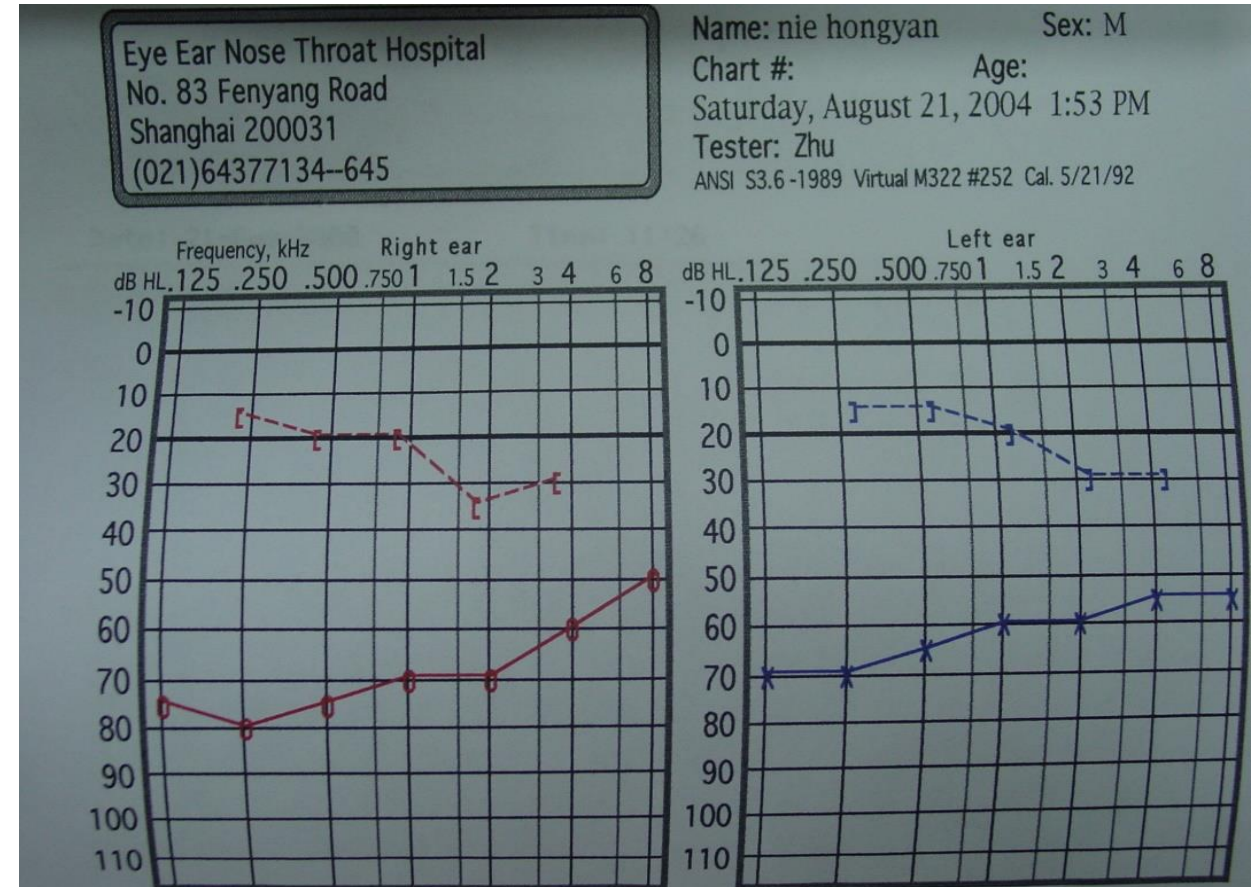
- Early stage: a decrease in air conduction in the low frequency, especially below 1000 Hz.
- As the disease progresses, the air line flattens. because the otosclerotic focus has a mass affect on the entire system, carhart notch is noted.
- Further progression of otosclerosis to involve the cochlea may result in increased bone conduction thresholds in high frequency, A-B gap exists in low frequency.
- More isolated cochlear otosclerosis may sometimes result in a mixed hearing loss with a “cookie-bite” pattern with both air and bone lines.





# Tests

- *Carhart notch*
  - *Carhart notch* is the hallmark audiologic sign of otosclerosis.
  - It is characterized by a decreased in the bone conduction thresholds of approximately 5 dB at 500 Hz, 10 dB at 1000 Hz, 15 dB at 2000 Hz, and 5 dB at 4000 Hz.

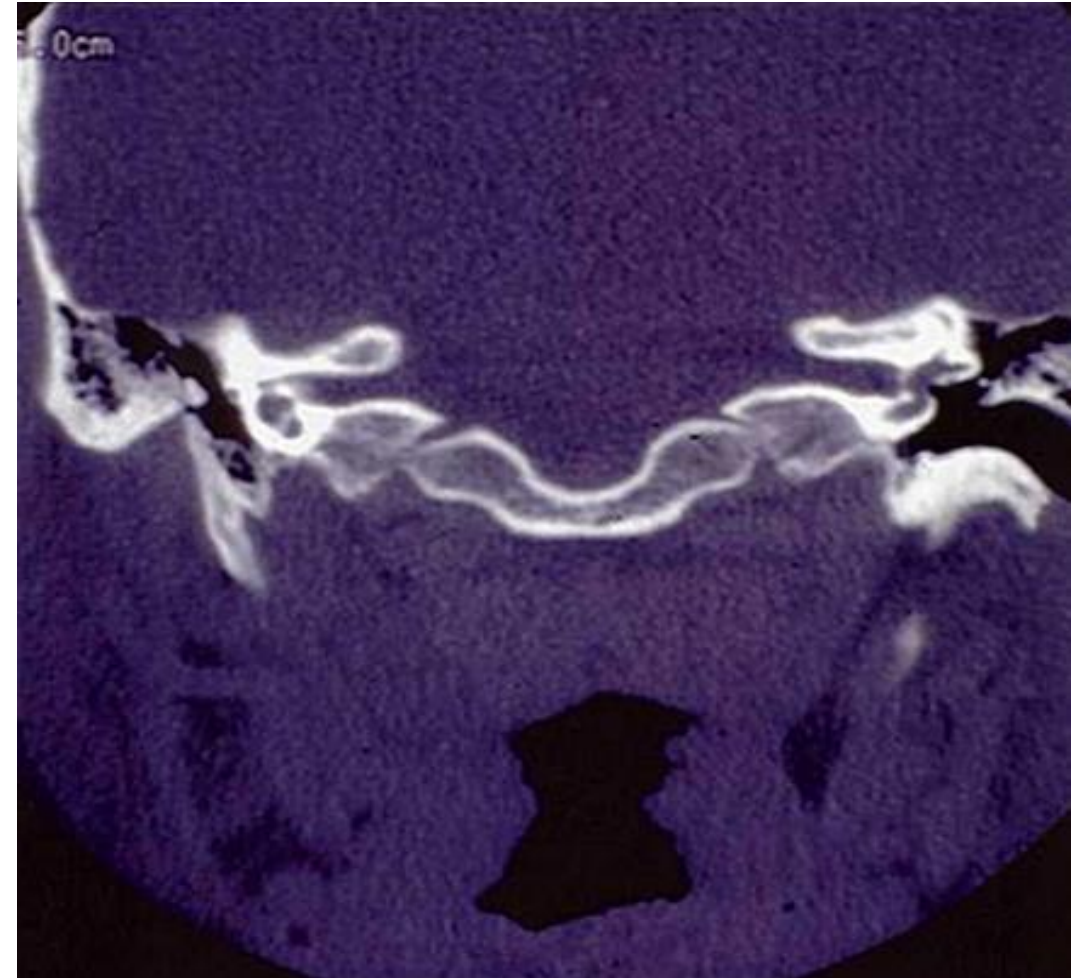


# Impedence Audiometry

- Type As (s-stiffness curve) tympanogram and is characteristic of advanced otosclerosis but more commonly, malleus fixation.

# Imaging

- CT can characterize the extent of the otosclerotic focus at the oval window
- CT scan can exclude capsular involvement when patients have significant mixed hearing loss
- An enlarged cochlear aqueduct may be seen which potentially causes perilymph gusher during footplate fenestration or removal.
- It reveal normal round window and normal mastoid pneumatization.



# Differential diagnosis

- **Ossicular discontinuity**

- conductive loss of 60 db usually without sensorineural component
- flaccid tympanic membrane on pneumatic otoscopy
- type Ad tympanogram

# Differential diagnosis

- **Malleus head fixation**

- when congenital, associated with other stigmata (aural atresia)
- presence of tympanosclerosis
- pneumatic otoscopy
- almost always associated with type As tympanogram (only in advanced otosclerosis)

# Differential diagnosis

- **Osteogenesis imperfecta**

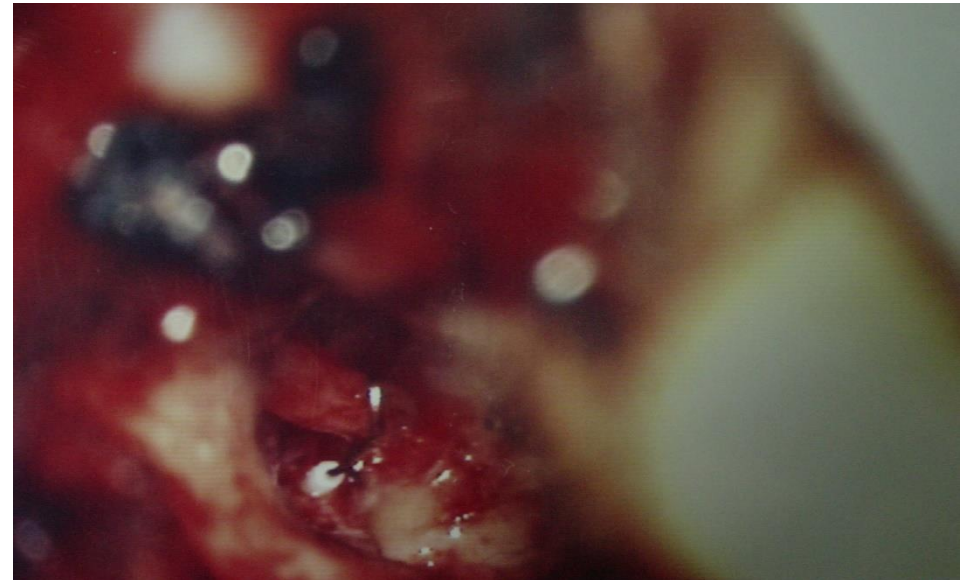
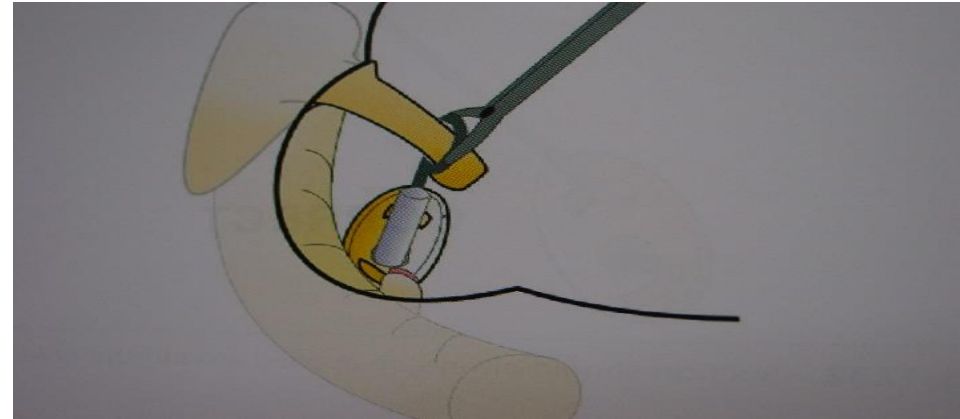
- presence of blue sclera
- h/o of multiple bone fractures
- CT – more commonly involves the otic capsule.

# *Surgical interventions*

- The best surgical candidate
  - good health with a socially unacceptable ABG,
  - a negative Rinne test,
  - excellent discrimination,
  - the desire for surgery after an appropriate period of time for deliberation.
  - Younger patients are more likely to develop re-ossification of the stapes footplate over their lifetime.

# *Surgical interventions*

- Stapedotomy
  - Less trauma to the oval window
  - Less possibility of damaging to the inner ear
  - In addition, revision surgery, if required, is easier due to preserved anatomy
- stapedectomy





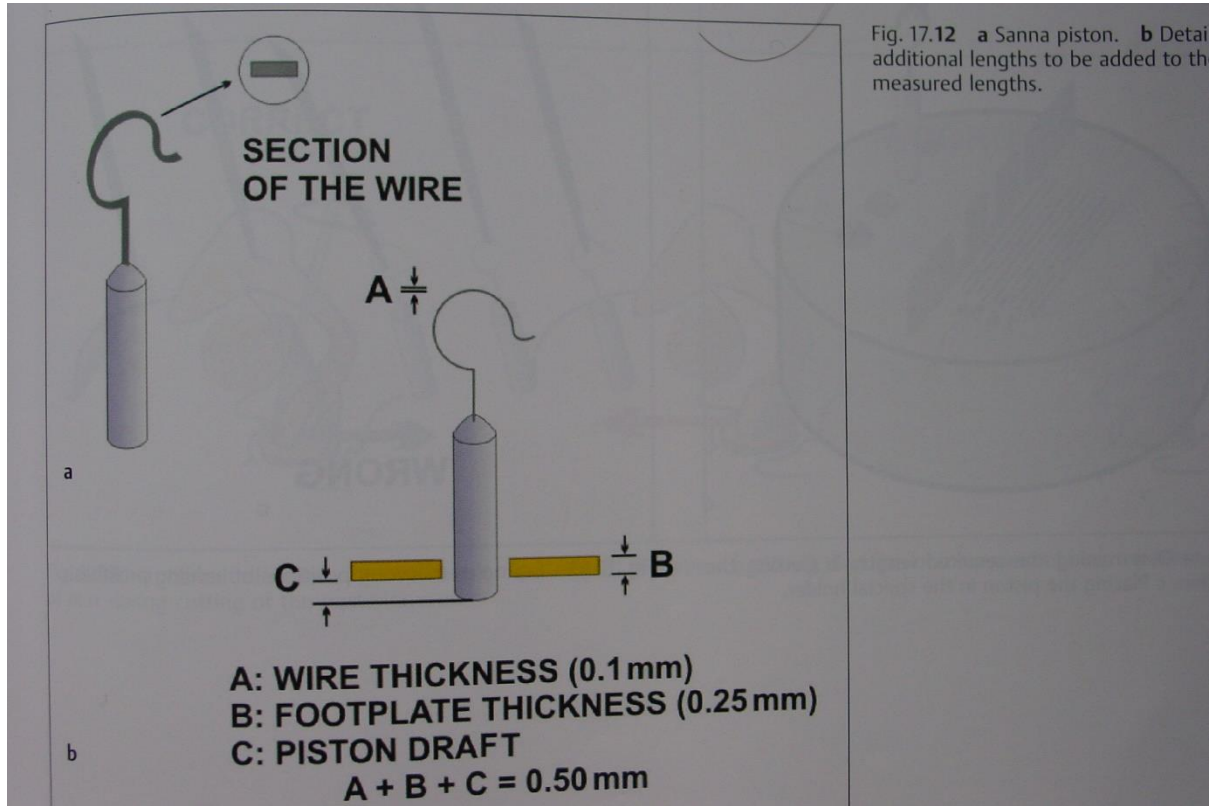
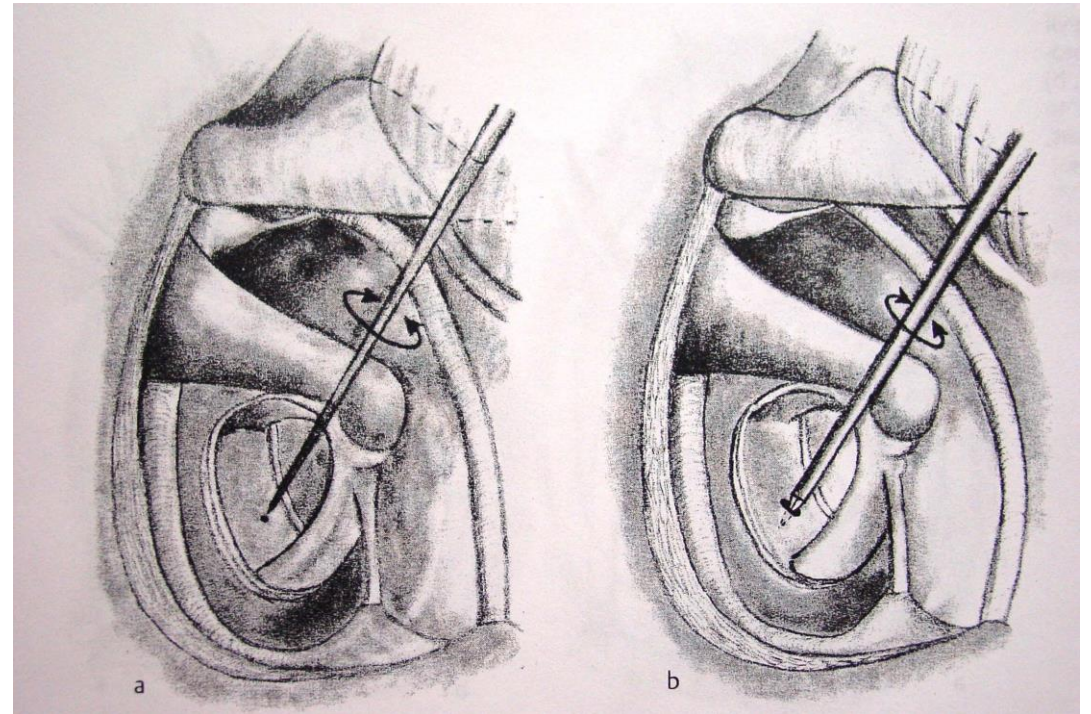


Fig. 17.12 a Sanna piston. b Detail additional lengths to be added to the measured lengths.



# *Non-surgical interventions*

- **Amplification:** hearing aids
  - Patients who do not want to undergo surgery for otosclerosis
  - patients who are not fit for surgery.

# *Non-surgical interventions*

- Medical treatment:
  - Usual dose is about 20-120mg of fluoride a day
  - Efficacy of the treatment can be evaluated 2 years later.
    - Schwartze's sign, and the degree of tinnitus and imbalance are reassessed, and a CT scan is repeated.
  - Once the disease was stable, the patient is placed on a life-long maintenance dose of about 25mg of fluoride a day.
  - 50% of patients have stabilization of their disease, 30% improve, and the rest continue to progress.

# *Non-surgical interventions*

- Indications for medical treatment
  - Not surgical candidates,
  - Decide against surgery,
  - Patient with SNHL or vestibular symptoms
  - positive Schwartze's sign may be given fluoride treatments for 6-12 months prior to surgery to induce the focus to mature and potentially prevent the progression of disease after surgery.
  - determined to be active during surgery, postoperative treatment can be initiated.

# Acoustic Neuroma

Dr H. P. Singh

Additional Professor

Department of Otorhinolaryngology & Head-Neck Surgery

Acoustic neuroma is also known as vestibular schwannoma, neurilemmoma or eighth nerve tumour.

# Incidence

Acoustic neuroma constitutes 80% of all cerebellopontine angle tumours and 10% of all the brain tumours.

# Pathology

It is a benign, encapsulated, extremely slow-growing tumour of the 8th nerve.

Microscopically, it consists of elongated spindle cells with rod-shaped nuclei lying in rows or palisades.

Bilateral tumours are seen in patients with neurofibromatosis.



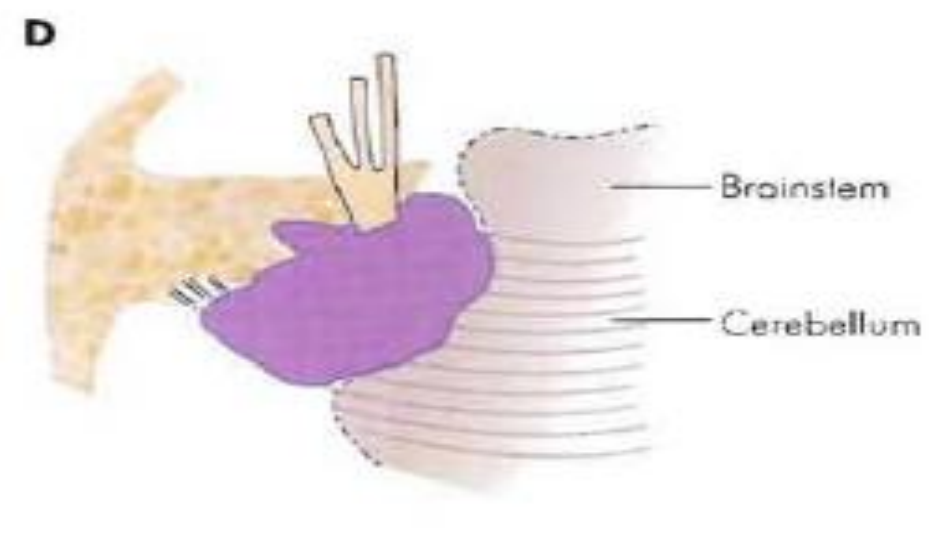
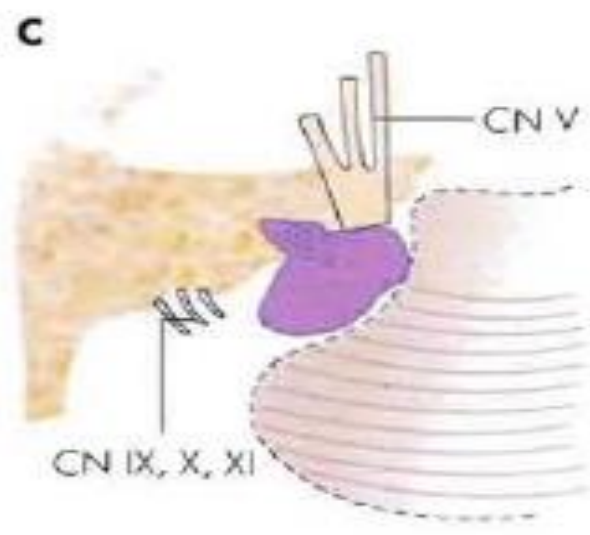
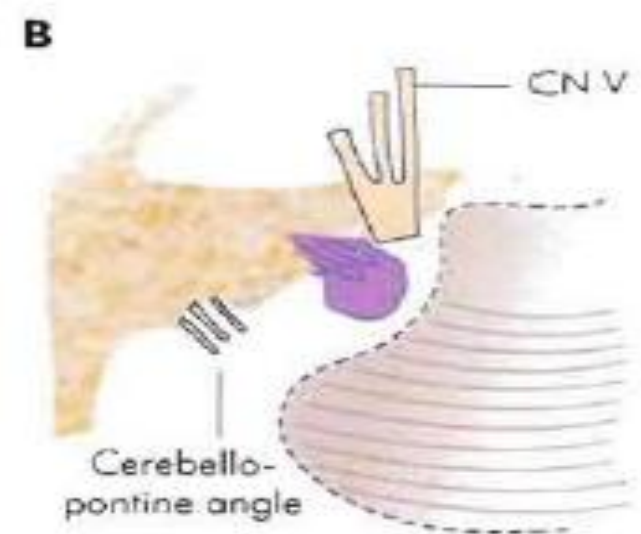
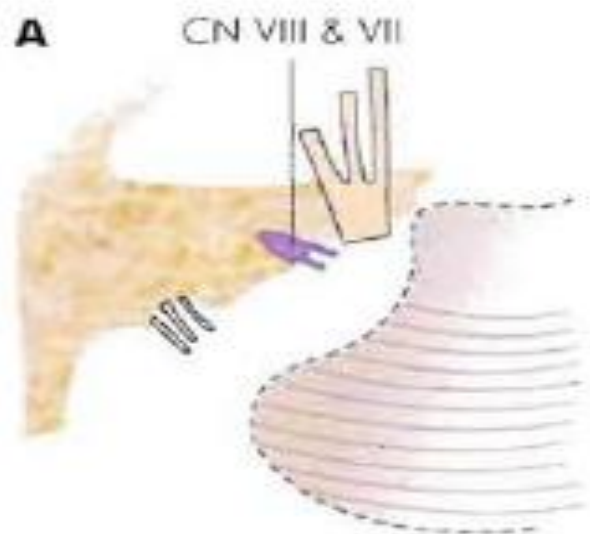
# Origin and Growth of Tumour

The tumour almost always arises from the Schwann cells of the vestibular, but rarely from the cochlear division of VIIIth nerve within the internal auditory canal.

As it expands, it causes widening and erosion of the canal and then appears in the cerebellopontine angle. Here, it may grow anterosuperiorly to involve Vth nerve or inferiorly to involve the IXth, Xth and XIth cranial nerves.

In later stages, it causes displacement of brainstem, pressure on cerebellum and raised intracranial tension.

The growth of the tumour is extremely slow and the history may extend over several years.



# Classification

Depending on the size, the tumour is classified as:

- (a) Intracanalicular (when it is confined to internal auditory canal)
- (b) Small size (up to 1.5 cm)
- (c) Medium size (1.5 to 4 cm)
- (d) Large size (over 4 cm)

# Clinical Features

- 1. Age and sex-** Tumour is mostly seen in age group of 40-60 years. Both sexes are equally affected.
- 2. Cochleovestibular symptoms-** They are the earliest symptoms when tumour is still intracanalicular and are caused by pressure on cochlear or vestibular nerve fibres or on the internal auditory artery. Progressive unilateral sensorineural hearing loss, often accompanied by tinnitus, is the presenting symptom in majority of cases. There is marked difficulty in understanding speech, out of proportion to the pure tone hearing loss. This feature is characteristic of acoustic neuroma.

Some patients may get sudden hearing loss.

**Vestibular symptoms-** are imbalance or unsteadiness. True vertigo is seldom seen.

## **Cranial nerve involvement.**

*Vth nerve.* This is the earliest nerve to be involved. There is reduced corneal sensitivity, numbness or paraesthesia of face. Involvement of this nerve indicates that the tumour is roughly 2.5 cm in diameter and occupies the cerebellopontine angle.

*VII th nerve.* Sensory fibres are affected early. There is hypoaesthesia of posterior meatal wall (Hitzelberger's sign), loss of taste (as tested by electrogustometry) and reduced lacrimation on Schirmer's test. Motor fibres are more resistant and are affected late. Delayed blink reflex may be an early manifestation.

*IXth and Xth nerves.* There is dysphagia and hoarseness due to palatal, pharyngeal and laryngeal paralysis.

*Other cranial nerves.* XIth and XIIth, IIIrd, IVth and VIth are affected when tumour is very large.

4. Brainstem involvement. There is ataxia, weakness and numbness of the arms and legs with exaggerated tendon reflexes. They are seen when long motor and sensory tracts are involved.

5. Cerebellar involvement. Pressure symptoms on cerebellum are seen in large tumours. This is revealed by finger-nose test, knee-heel test, dysdiadochokmesia, ataxic gait, inability to walk along a straight line with tendency of fall to the affected side.

6. Raised intracranial tension. This is also a late feature. There is headache, nausea, vomiting, diplopia due to VIth nerve involvement and papilloedema with blurring of vision.

# Investigations and Diagnosis

Attempts should be made to diagnose the tumour in its otological phase when it is still intracanalicular. This is possible when all cases of unilateral sensorineural hearing loss with tinnitus or imbalance are carefully evaluated.

## **Audiological tests:**

a) Pure tone audiometry- sensorineural hearing loss, more marked in high frequencies.

b ) Speech audiometry- poor speech discrimination and this is disproportionate to pure tone hearing loss. Roll-over phenomenon, i.e. reduction of discrimination score when loudness is increased beyond a particular limit is most commonly observed.

(c) Recruitment phenomenon is absent.

(d) Short Increment Sensitivity Index (SISI) test will show a score of 0-20% in 70-90% of cases.

(e) Threshold tone decay test shows retrocochlear type of lesion.

2. Stapedial reflex decay test

3. Vestibular tests. Caloric test will show diminished or absent response in 96% of patients. When tumour is very small, caloric test may be normal.

4. Neurological tests. Complete examination of cranial nerves, cerebellar functions, brainstem signs of pyramidal and sensory tracts should be done. Fundus is examined for blurring of disc margins or papilledema.

5. Radiological tests. (a) *Plain X-rays* (transorbital, Stenver's, Towne's and submentovertical views) give positive findings in 80% of patients. However, small intracanalicular tumours are not detected.

(b) *CT scan*. A tumour that projects even 0.5 cm into the posterior fossa can be detected by a CT scan. If combined with intrathecal air, even the intrameatal tumour can be detected. CT scan has replaced earlier methods of pneumoencephalography and myodil meatography.

(c) *MRI with gadolinium contrast*. It is superior to CT scan and is the **gold standard** for diagnosis of acoustic neuroma. Intracanalicular tumour, of even a few millimetres, can be easily diagnosed by this method.

(d) *Vertebral angiography*. This is helpful to differentiate acoustic neuroma from other tumours of cerebellopontine angle when doubt exists.

6. Evoked response audiometry (BERA). It is very useful in the diagnosis of retrocochlear lesions. In the presence of VIIIth nerve tumour, a delay of  $>0.2$  milisec in wave V between two ears is significant.

7. CSF examination. Protein level is raised. Lumbar puncture is usually avoided.



# Differential Diagnosis

- Acoustic neuroma should be differentiated from the cochlear pathology (i.e. Meniere's disease) and other cerebellopontine angle tumours, e.g. meningioma, primary cholesteatoma and arachnoidal cyst

**Table 18.1** Tumours of cerebellopontine angle

- Acoustic neuroma
- Meningioma
- Epidermoid (cholesteatoma)
- Arachnoid cyst
- Schwannoma of other cranial nerves (e.g. CN V > VII > IX, X, XI)
- Aneurysm
- Glomus tumour
- Metastasis

# Treatment

***Surgery*** -Surgical removal of the tumour is the treatment of choice. Surgical approach will depend upon the size of tumour.

The various approaches are:

1. Middle cranial fossa approach.
2. Trans-labyrinthine approach .
3. Suboccipital approach.
4. Combined translabyrinthine-suboccipital approach.

# *Radiotherapy*

- *Conventional radiotherapy* by external beam has **no role** in the treatment of acoustic neuromas due to low tolerance of the central nervous system to radiation.
- *Gamma knife surgery*. It is a form of stereo-tactic radiotherapy where radiation energy is converged on the tumor, thus minimizing its effect on the surrounding normal tissue. This causes arrest of the growth of the tumor and also reduction in its size . It can be used in patients who refuse surgery or have contra indications to surgery or in those with a residual tumor.



Thanks for your attention!